

## ***Kalanchoe lanceolata* poisoning in Brahman cattle in Zimbabwe: the first field outbreak**

Cecilia Masvingwe<sup>a</sup> and M Mavenyengwa<sup>b</sup>

### **ABSTRACT**

Field outbreaks of *Kalanchoe lanceolata* poisoning in cattle on a commercial farm in Zimbabwe are reported. The clinical signs and pathological lesions observed in field cases resembled those reproduced in an experimental cow and were consistent with acute cardiac glycoside poisoning.

**Key words:** acute cardiotoxicity, cattle, *Kalanchoe lanceolata*, poisoning.

Masvingwe C, Mavenyengwa M *Kalanchoe lanceolata* poisoning of Brahman cattle in Zimbabwe: the first field outbreak. *Journal of the South African Veterinary Association* (1997) 68(1): 18–20 (En.). Department of Preclinical Veterinary Studies, Faculty of Veterinary Science, University of Zimbabwe, PO Box MP167, Mt Pleasant, Harare, Zimbabwe.

### **INTRODUCTION**

*Kalanchoe lanceolata* is an erect, usually unbranched annual and occasionally perennial succulent plant standing about 1 m in height<sup>4</sup>. On the farm near Chegutu (about 140 km west of Harare) where the outbreak occurred, it stood about 40 cm at flowering. The flowers are star-shaped and the four corolla lobes a mixture of apricot and yellow. The inflorescences are borne on the axils of upper leaves. Of the family Crassulaceae, the genera *Kalanchoe*, *Cotyledon* and *Tylecodon* contain bufadienolides that are capable of causing acute cardiac toxicity and a chronic parietic syndrome<sup>1–3</sup>, depending on dose and duration<sup>4</sup>.

The distribution of *K. lanceolata* in Zimbabwe has not been reported fully but the plant has been recorded from highveld areas such as Chegutu, Zvimba, Mazowe and Mayo. It is known to grow in the shade of trees and bushes and often forms dense stands<sup>4</sup>. On the affected farm it grew densely on richer soils, for example on anthills, and was associated with fields of overgrazed *Cynodon dactylon*.

### **HISTORY OF OUTBREAKS**

Mortalities from an unknown cause occurred in a Brahman breeding herd on a commercial farm near Chegutu about

140 km west of Harare. These outbreaks were observed during the rainy seasons of 1991/92, 1992/93 and 1993/94. The affected herd was grazed separately on an extended rotation system utilising two large undivided paddocks of a partly-cleared woodland. Investigations during the 1991/92 and 1992/93 outbreaks, when an unspecified number of animals died, were inconclusive. At that stage the animals presented with diarrhoea, excessive voiding of urine, a pounding, rapid heart beat, muscle tremors and frothing. In the terminal stages, affected animals would isolate themselves, charge at attendants, tire easily, collapse and die. Death occurred within 24–48 h of onset of clinical signs. At necropsy no significant pathological lesions were detected but the investigators noted remission of clinical signs and deaths after the relocation of animals to a different paddock.

During the 1993/94 outbreak, which we investigated, 22 animals were affected over a period of 2 months. Clinical signs were similar to those described above. About half of them died or were destroyed during the aggressive phase. The remainder seemed to respond to oral gavage, by the referring veterinarian, with 10 l of cow's milk per animal.

Necropsies performed on 3 animals that died during the 1993/94 outbreak revealed a mucoïd to haemorrhagic gastroenteritis, brain oedema and petechiation of the epicardium. Histopathological examination showed scattered areas of fine granular degeneration of myofibres and a haemorrhagic gastroenteritis.

### **FIELD INVESTIGATION**

A farm visit was undertaken to investigate possible toxic causes for this condition, during which a necropsy was performed on a cow reported to have died after showing signs similar to those described above. Grossly, an ulcerative haemorrhagic gastroenteritis, hydropericardium with fibrin strands, petechiation of the epicardium and moderately dark discolouration of the myocardium were observed. After due consideration, plant intoxications causing diarrhoea and gastroenteritis were regarded as the most probable diagnosis. Samples of the brain, kidney, heart, liver, intestines and skeletal muscles were collected and preserved in 10 % buffered formalin for histopathological evaluation. Histopathological lesions were similar to those previously noted.

The paddocks were surveyed for poisonous plants. Specimens of known poisonous and unknown plants were collected for positive identification by the National Herbarium, Harare. Amongst the plant species collected were the poisonous *Pavetta schumanniana*, *Acacia sieberana*, *Solanum delagoense* and *Kalanchoe lanceolata*.

A second visit to the farm was undertaken to verify the population densities of the poisonous plants identified and to establish whether any of these plants had been grazed. A survey of the 2 paddocks revealed abundant *K. lanceolata* with evidence that it had been grazed. A sack was filled with the plant for feeding trials.

### **FEEDING TRIAL**

Mazowe Field Station, a government veterinary research farm 30 km north of Harare, was used for the feeding trial. There was no history of similar outbreaks on this farm and *Kalanchoe lanceolata* was not present. Initially, a Brahman cow was selected for the trial. She proved too aggressive to be handled and a 5-year-old Friesian cow, weighing about 450 kg, was then used. The cow was starved for half a day but had access to water. It was then hand-fed 7 kg of *K. lanceolata* (stems and leaves) over 2 hours, and thereafter

<sup>a</sup>Department of Preclinical Veterinary Studies, Faculty of Veterinary Science, University of Zimbabwe, PO Box MP 167, Mount Pleasant, Harare.

<sup>b</sup>Central Veterinary Laboratory, Harare.

Received: March 1996. Accepted: January 1997.

allowed to graze with the rest of the herd and monitored twice a day for signs of illness. Clinical signs were observed from 2 days post-ingestion and included isolation from the rest of the herd, tachycardia, weakness, diarrhoea and frothing at the mouth. All these signs, with the exception of frothing, persisted until death. The animal died in sternal recumbency, with a backward extension of hind legs, 2 weeks post-ingestion (Fig. 1).

A necropsy was performed on the farm. Gross examination revealed epicardial haemorrhages and myocardial congestion. A muco-haemorrhagic enteritis with paintbrush mucosal haemorrhages, abomasal hyperaemia and scattered abomasal ulcers about 5 mm in diameter were also noted. The abomasal and ruminal contents were voluminous and fluid. Tissue samples of the heart, liver, kidneys, brain, skeletal muscles, lungs and intestines were collected and fixed in 10 % buffered formalin for histopathological examination.

The heart microscopically showed myofibre oedema and degeneration indicated by granularity, swelling and vacuolation, and interfibre oedema evidenced by widening of interfibre spaces (Fig. 2). Hyperaemia and haemorrhage in the myocardium were also present. Congestion and scattered haemorrhages were noted in the mucosa and submucosa of the intestines.

**DISCUSSION**

The clinical signs and pathological lesions from field cases appeared similar to those observed in the feeding trial and conform to those described by other workers<sup>5,7,8</sup>. Aggression, as observed in field cases, was only directed towards attendants and not towards objects or other animals as would have been expected in a true neurological syndrome. It is possible that this could have been a breed-related stress response of Brahman cattle and probably explains why this phenomenon was not noticed in the Friesian cow used experimentally.

The clinical syndrome observed in both the natural cases and the experimental case appear to be consistent with acute cardiac glycoside poisoning. Experimental cases of the bufadienolide-containing, closely related *Bryophyllum* (= *Kalanchoe tubiflorum*) poisoning in cattle have been treated successfully with activated charcoal<sup>6</sup>. While oral gavage with milk appeared to alleviate field cases treated early, the mechanism of action is not clear and requires further investigation.

This study indicates that *K. lanceolata*



Fig. 1: Experimental animal in sternal recumbency with backward extension of the hind legs.

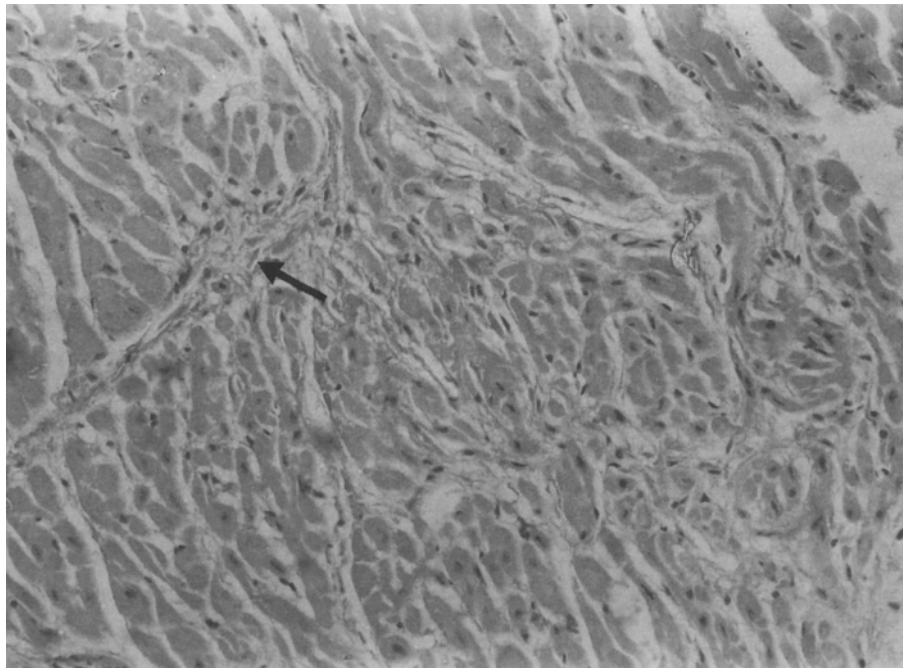


Fig. 2: Heart: widening of interfibre spaces (indicative of oedema) and swelling of fibres; mild interstitial fibrosis (arrow). HE x300.

was the most probable cause of the unexplained deaths that occurred on the affected farm. The investigation was limited by the availability of only one experimental animal of a different breed for clinical trials. However, the similarity of the field and experimental syndromes, especially the pathological lesions, and

the finding of abundant *K. lanceolata* with evidence that it had been grazed, were highly suggestive of a common aetiology. Differential diagnoses for the syndrome should include bufadienolide poisoning due to other plants such as *Urginea sanguinea* (Liliaceae), *Cotyledon* and *Tylecodon* spp. (Crassulaceae).

## ACKNOWLEDGEMENTS

We thank Messrs R B Drummond and S Mavi, National Herbarium, Harare, for specialist botanical assistance, and Messrs S Gove, A Toto, W Shumba, P Mlambo and Dr G Tafirei for technical assistance. We also thank Prof. K Mohan for critical comments on the manuscript. Experimental animals were provided by the Department of Veterinary Services and the project was co-funded by the University of Zimbabwe Research Board. The histopathological findings were confirmed by Dr R Lindberg, Department of Pathology, Faculty of Veterinary Medicine, Swedish University of Agricultural Sciences, Uppsala.

## REFERENCES

1. Anderson L A P, Schultz R A, Joubert J P J, Prozesky L, Kellerman T S, Erasmus G L, Procos J 1983 Krimpsiekte and acute cardiac glycoside poisoning in sheep caused by bufadienolides from the plant *Kalanchoe lanceolata* (Forssk). *Onderstepoort Journal of Veterinary Research* 50: 295–300
2. Anderson L A P, Steyn P S, Van Heerden E R 1984 The characterisation of two novel bufadienolides, lanceotoxins A and B from *Kalanchoe lanceolata* (Forssk) Pers. *Journal of the Chemical Society Perkin Transactions* 1573–1575
3. Anderson L A P, Schultz R A, Kellerman T S, Kotze S M, Prozesky L, Erasmus G L, Labuschagne L 1985 Isolation and characterisation of and some observations on poisoning by bufadienolides from *Cotyledon orbiculata* L. var. *orbiculata*. *Onderstepoort Journal of Veterinary Research* 52: 21–24
4. Kellerman T S, Coetzer J A W, Naudé T W 1990 *Plant poisonings and mycotoxicoses of livestock in southern Africa*. Oxford University Press, Cape Town
5. McKenzie R A, Dunster P J 1986 Hearts and flowers: *Bryophyllum* poisoning of cattle. *Australian Veterinary Journal* 63: 222–227
6. McKenzie R A, Dunster P J 1987 Curing *Bryophyllum tubiflorum* poisoning of cattle with activated carbon, electrolyte replacement solution and antiarrhythmic drugs. *Australian Veterinary Journal* 64: 211–214
7. McKenzie R A, Franke F P, Dunster P J 1987 The toxicity to cattle and bufadienolide content of six *Bryophyllum* species. *Australian Veterinary Journal* 64: 298–301
8. McKenzie R A, Franke F P, Dunster P J 1989 The toxicity for cattle of bufadienolide cardiac glycosides from *Bryophyllum tubiflorum* flowers. *Australian Veterinary Journal* 66: 374–376