

Clinical aspects of an outbreak of papillomatous digital dermatitis in a dairy cattle herd

I Yeruham^{a*} and S Perl^b

ABSTRACT

Digital skin lesions and lameness of several weeks duration, with a morbidity rate of 28.3 %, was reported in a group of 60 Holstein-Israeli dairy cows in various stages of lactation. A clinical survey was performed to monitor recovery and to confirm eradication of bovine papillomatous digital dermatitis in the herd. The combined effects of intensive individual treatment of the 4 lame cattle with procaine penicillin and metronidazole, and subjecting all animals in the herd to a foot bath with a solution composed of formaldehyde and sodium hydroxide twice a week for 12 weeks, were found to achieve a dramatic positive response in all affected cows in the herd. During a 1-year follow-up period no recurrence and/or new cases have been diagnosed.

Key words: dairy cattle, foot bath, papillomatous digital dermatitis, *Treponema pertenuis*.

Yeruham I, Perl S **Clinical aspects of an outbreak of papillomatous digital dermatitis in a dairy cattle herd.** *Journal of the South African Veterinary Association* (1998) 69(3): 112–115 (En.). 'Hachaklait', Gadera and The Koret School of Veterinary Medicine, The Hebrew University of Jerusalem, PO Box 12, Rehovot 76100, Israel.

INTRODUCTION

Papillomatous digital dermatitis (PDD) is an infectious and contagious disease of the skin of bovine digits^{1,3,4,14,16}, and during the past 20 years it has become an important cause of lameness in dairy cattle worldwide^{1,3,6,7,9,10,12,16,18,20,24}.

The economic importance of papillomatous digital dermatitis is attributable to decreased milk yield, weight loss, impaired reproductive performance, increased numbers of culled cattle, and costs of treatment and control¹⁶. Little is known about the cause and epidemiology of the disease. It is believed to be a multifactorial disease in which infectious agents are primarily involved^{4,10,13,14,19}. Some reports have focused on the role played by spirochaete organisms of the genus *Treponema* associated with PDD; these appear to be among the predominant organisms found invading the stratum spinosum and dermal papillae^{4,14,17,19–21}.

A number of bacteria have been isolated from PDD lesions but none has been shown with certainty to play a role in the

pathogenesis of the lesion^{4,8,13,22}. There is no evidence of viral involvement¹⁵. The use of foot baths containing solutions of formaldehyde, copper sulphate or zinc sulphate is the most common treatment for cattle with PDD^{11,22}. PDD is responsive to either parenteral or topical antibiotic therapy, suggesting a bacterial role in the disease process^{14,15}.

The present report concerns an infectious, acute and rapidly progressive outbreak of bovine papillomatous digital dermatitis in a dairy cattle herd in Israel.

CASE HISTORY

The disease was seen in a herd of 60 dairy cows in various stages of lactation. All age categories were affected, from 1st lactation to older cows; 12 (70.6 %) of the 17 affected animals were 2nd lactation and older cows, and only 5 (29.4 %) were 1st-calving cows. The hooves of the herd were routinely trimmed twice a year.

The cows were kept in a loose-housing system under continually wet conditions. The outbreak of PDD occurred in August. Lesions were evaluated in the milking parlour before initiation of treatment and again at 2-week intervals. Closer inspection of the affected limbs was performed after using a medium-pressure water hose, and the feet were cleaned. Gross lesions usually appeared in 3 forms: (1) early lesions on the plantar aspect were circular and developed proliferative masses with projections on their surfaces

(strawberry-like) (Fig. 1); these lesions were near or slightly proximal to the juncture of the bulbs of the heels. (2) Later, the lesion became more extensive, with a verrucose appearance (papillomatous-like), with superficial necrosis (Fig. 2) and a foul odour; the condition appeared to be restricted to the dermis, with no involvement of the subcutaneous tissues. (3) Lesions in 2 cows developed at the dorsal aspect of the interdigital cleft, with interdigital hyperplasia; no swelling of the coronet was seen. Milk yield was reduced only in the lame cows, an average drop of 5 litres per cow per day (14 % of the daily milk production).

The lameness evaluation was performed by observing the cows individually as they walked at a normal pace in a vacant concrete alley.

Morbidity was high: 17/60 cows clinically examined were seen to be affected on the hind limbs only, 4 on both legs, 9 on the right and 4 on the left. Four cows showed varying degrees of lameness; they shifted weight from one foot to another and appeared uncomfortable when standing in the yards.

No pathogenic bacteria were identified when material scraped from lesion surfaces of 4 cows was stained with Gram's stain and examined microscopically. Aerobic and anaerobic cultures from the biopsies plated on ox-blood agar and on McConkey media also failed to yield pathogenic microorganisms.

Biopsies were taken from 4 affected cows, and parts were fixed in 10 % neutral buffered formalin and processed for histology. The histopathological changes were identical in biopsies taken from lesions of the affected cows: marked epidermal hyperplasia with hyperkeratosis, basal cells with prominent nucleoli, and acanthosis. Superficial epidermal necrosis was present and was associated with purulent inflammation (Figs 3, 4). Silver-staining, using the technique of Warthin-Starry, was performed on the tissue samples. Organisms similar to those described by Read *et al.*¹⁴ were present deep in the lesion – a large number of filamentous to spiral organisms of the spirochaete group.

^aHachaklait', Gadera and The Koret School of Veterinary Medicine, The Hebrew University of Jerusalem, PO Box 12, Rehovot 76100, Israel.

^bThe Kimron Veterinary Institute, PO Box 12, Bet Dagan, 50250, and the Koret School of Veterinary Medicine, the Hebrew University of Jerusalem, Rehovot 76100, Israel.

*Correspondence to: Dr I. Yeruham, 4 Hagoren St., 70700 Gadera, Israel.

Received: December 1997. Accepted: June 1998.

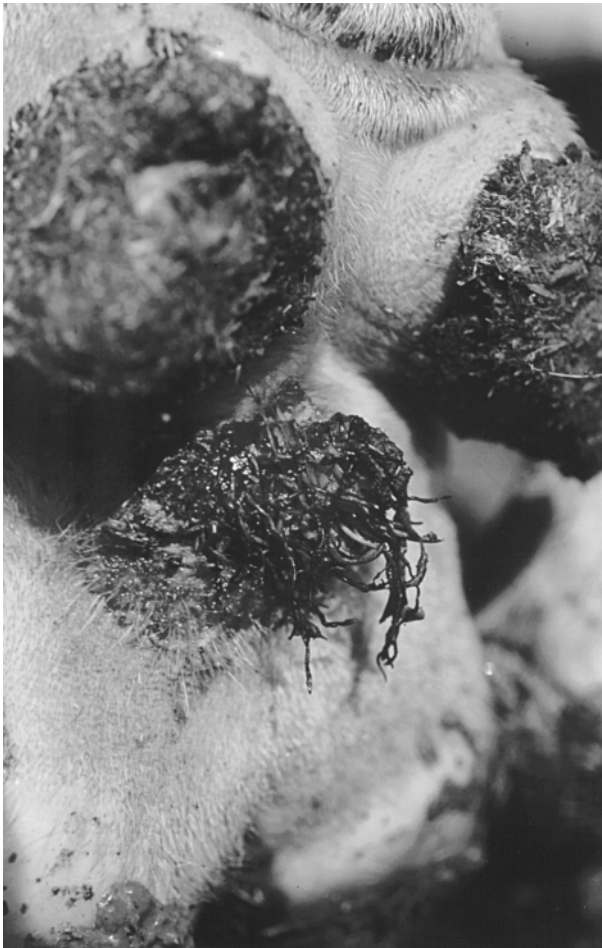

Fig. 1: **Proliferative mass lesion** (strawberry-like).



Fig. 2: **Lesion with verrucose appearance** (papillomatous-like).

We found that a 5 % formalin solution combined with 5 % sodium hydroxide in a foot bath (2 m long and 15 cm deep), used twice a week, resulted in a marked improvement of the condition after the 2nd treatment, and offers good control of the disease. Four weeks after the initiation of the treatment programme (a total of 8 treatments), all affected cows had completely recovered. The legs of the cows were washed clean of loose faeces and detritus before they entered the foot bath. The foot bath was cleaned weekly. The entire herd continued to receive the same treatment for 12 weeks. During the follow-up period of 1 year no new cases of digital dermatitis were recorded.

The 4 lame cattle were, in addition to the above treatment, treated parenterally with procaine penicillin (Renyamina, Israel) 22 000 IU/kg and metronidazole (Renyamina, Israel) 50 mg/kg for 3 consecutive days, which resulted in cessation of lameness and regression of lesions.

DISCUSSION

The spirochaete-like organisms associated with the papillomatous digital dermatitis (PDD), which were found deep

in the epidermis, in silver-stained tissue sections from 4 affected cows in the described outbreak, may apparently play an important role in the pathogenesis of PDD^{2,9,14,15}.

Apart from spirochaete-like organisms other microorganisms that have been suspected to be involved in this condition are *Fusobacterium necrophorum*, *Bacteroides* spp.²² and *Campylobacter faecalis*⁴. The sudden onset and the rapid spread of the disease through the herd, the histological findings, and the response to treatment suggest an infectious aetiological agent. Until Koch's postulates can be fulfilled, the role of spirochaetes remains uncertain.

Bovine papillomatous digital dermatitis histologically resembles the human tropical disease 'yaws', a skin disease of the legs caused by the spirochaete *Treponema pertenue* (*Treponema pallidum* subspecies *pertenue*)^{2,4,14,15,16,19}, which is also highly responsive to parenteral antibiotics. Invasiveness of the spirochaete has been demonstrated by a modified Steiner silver impregnation method for paraffin sections¹⁴. It seems that most reported outbreaks of PDD involve dairy herds of the Friesian and

Holstein breeds and their crosses²⁴.

Papillomatous digital dermatitis occurs most commonly on the hind limbs. Gross lesions in the reported herd appeared in 3 forms: demarcated red, raw granular areas (*strawberry-like*); yellow, grey or brown papillary proliferation (*papillomatous-like*), and interdigital proliferative dermatitis.

Morbidity of PDD in dairy herds in different countries varies widely, from 12 to 80 %^{1,3,5,11,16,18}. In the recent outbreak the morbidity rate reached 28.3 %. The extensive outbreak of PDD followed the introduction of purchased heifers into the herd during the previous few months. Dairy herds for which replacement heifers were purchased, were more likely to be affected by PDD through the introduction of infected animals, than so-called 'closed herds'^{11,18}.

Based on our cumulative data it appears that PDD prevalence has a seasonal pattern. Morbidity in the described herd and also on other dairy farms in Israel (unpublished data) is high mostly during the summer months (June–October). It seems that the housing of the cattle all year round in barns, in a region with a hot

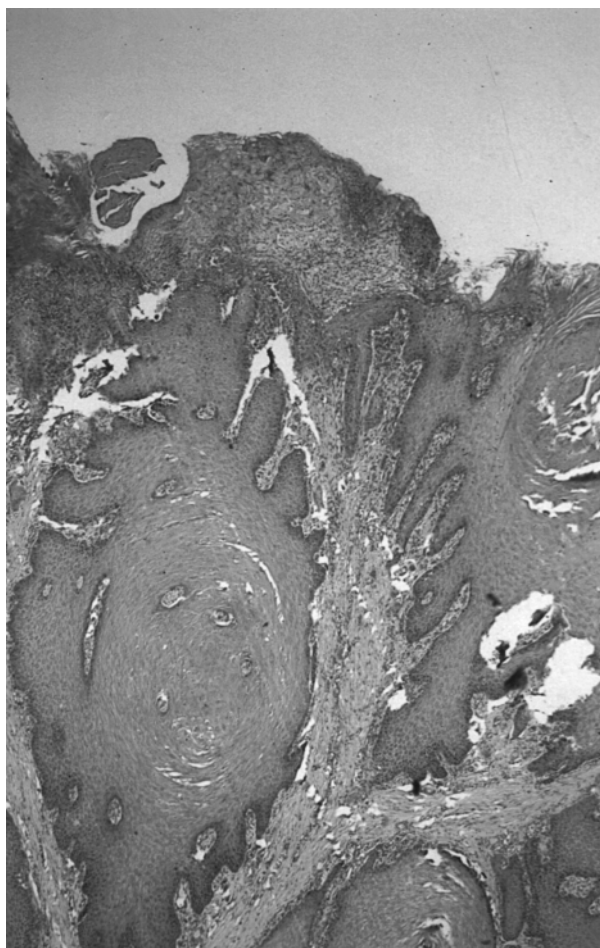


Fig. 3: Papillary proliferation of the squamous epithelium and a focal area of necrosis (HE; ×20).

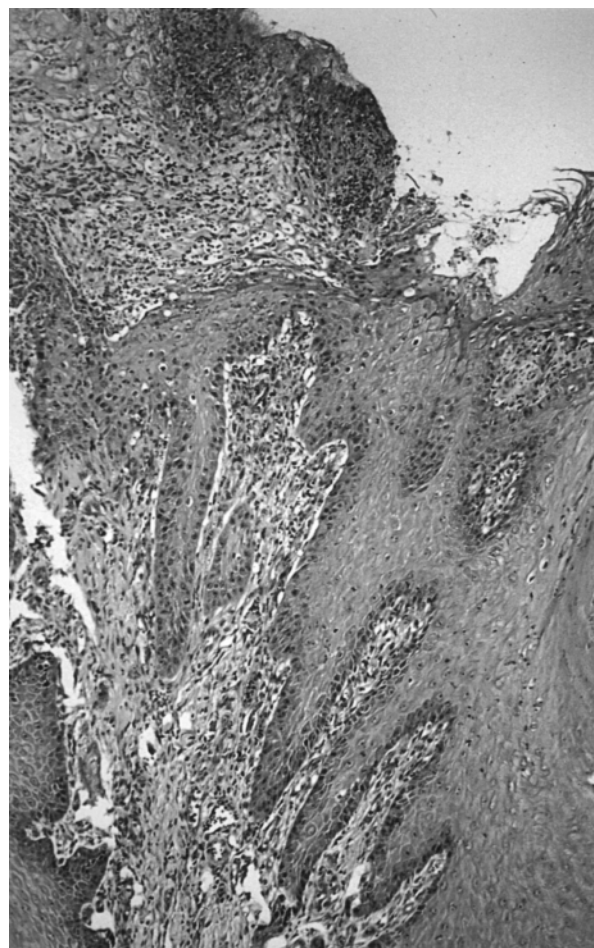


Fig. 4: Elongated rete ridges, necrosis, infiltration with inflammatory cells and cell debris (HE; ×40).

and humid climate, facilitates the spread of the infection through the herd.

Peterse¹², Raven¹³, Greenough *et al.*⁸ and Rodriguez-Lainz *et al.*¹⁸ indicated that the predisposing conditions for PDD are a warm and wet environment for housed cattle – conditions that exist in countries with tropical and subtropical climates. There is general agreement that the condition occurs primarily while the cows are housed¹. It seems that improved management and ventilation and dry bedding may reduce the prevalence of PDD in dairy cattle herds.

Treatment of the condition in the outbreak reported here consisted of cleaning the feet of cows on their way into the milking parlour, with a high-pressure water hose, and a foot bath twice a week in a solution of 5 % formalin and 5 % sodium hydroxide for 12 weeks. We recommend that all animals in the affected herd should be foot-bathed, with the affected cows being kept in the foot bath for at least 15 min, and parenteral treatment of the lame cows with procaine penicillin and metronidazole for 3 consecutive days. The described

treatment and control programme proved to be successful in treatment and eradication of this apparently infectious disease from the affected herd.

It is to be hoped that due attention will be paid to such a potentially widespread infectious disease that causes economic losses in dairy cattle herds, and its spread by intensive animal trading, before it becomes endemic in many herds.

REFERENCES

1. Blowey R W, Sharp W M W 1988 Digital dermatitis in dairy cattle. *Veterinary Record* 122: 506–508
2. Blowey R W, Done S H, Cooley W 1994 Observation on the pathogenesis of digital dermatitis in cattle. *Veterinary Record* 135: 115–117
3. Cheli R, Mortellaro CM 1974 Digital dermatitis. *Proceedings of the 8th International Conference on Diseases of Cattle, Milan, Italy, 1974*, 208–213
4. Dopfer D, Koopmans A, Meijer F A, Szakall I, Schukken Y H, Klee W, Bosma R B, Cornelisse J L, Van Asten A J, Ter Huurne A A 1997 Histological and bacteriological evaluation of digital dermatitis in cattle, with special reference to spirochaetes and *Campylobacter faecalis*. *Veterinary Record* 140: 620–623
5. Frankena K, Stassen E N, Noordhuizen J P, Goelema J O, Schipper J, Smelt H, Romkema H 1991 Prevalence of lameness and risk indicators for digital dermatitis (Mortellaro disease) during pasturing and housing of dairy cattle. In: Rowlands G J (ed.) *Proceedings of the Annual Meeting of the Society of Veterinary Epidemiology and Preventive Medicine, London, UK 1991*: 107–118
6. Frankena K, Van Keulen K A S, Noordhuizen J P, Noordhuizen-Stassen E N, Gundelach J, De Jong D, Saedt I 1993 A cross-sectional study of prevalence and risk factors of dermatitis interdigitalis in female calves in the Netherlands. *Preventive Veterinary Medicine* 17: 137–144
7. Gourreau J M, Scott D W, Rousseau J F 1992 La dermatite digitée des bovins. *Le Point Veterinaire* 24: 49–57
8. Greenough P R, MacCallum F J, Weaver A D 1981 *Lameness in cattle*. John Wright, Bristol
9. McLennan M W, McKenzie R A 1996 Digital dermatitis in a Friesian cow. *Australian Veterinary Journal* 74: 314–315
10. Mortellaro M C 1994 Digital dermatitis. *Proceedings of the 8th International Symposium on Disorders of the Ruminant Digit*: 137–141
11. Nutter W T, Moffitt J A 1990 Digital dermatitis control. *Veterinary Record* 126: 200–201
12. Peterse D J 1986 Papillomatous digital dermatitis. *Proceeding of the 14th International Meeting on Diseases of Cattle, Dublin 1986*. Dublin World Association for Buiatrics,

- Irish Cattle Veterinary Association: 1015–1024
13. Raven T E 1985 *Cattle footcare and claw trimming*. Farming Press, Ipswich
 14. Read D H, Walker R L, Castro A E, Sundberg J P, Thurmond M C 1992 An invasive spirochaete associated with interdigital papillomatosis of dairy cattle. *Veterinary Record* 130: 59–60
 15. Read D H, Walker R L 1994 Papillomatous digital dermatitis and associated lesions of dairy cattle in California: pathologic findings. *Proceedings of the 8th International Symposium on Disorders of the Ruminant Digit*: 156–158
 16. Rebhum W C, Payne R M, Kings J M, Wolfe M, Begg S N 1980 Interdigital papillomatosis in dairy cattle. *Journal of the American Veterinary Medical Association* 177: 437–440
 17. Rijpkema S G T, David G P, Hughes S L, Woodward M J 1997 Partial identification of spirochaetes from two dairy cows with digital dermatitis by polymerase chain reaction analysis of the 16 S ribosomal RNA gene. *Veterinary Record* 140: 257–259
 18. Rodriguez-Lainz A, Hird D W, Carpenter T E, Read D H 1996 Case-control study of papillomatous digital dermatitis in southern California dairy farms. *Preventive Veterinary Medicine* 28: 117–131
 19. Sauvageau R, Higgins R, Jacques M, Bouchard E 1994 Bovine digital dermatitis. *Canadian Veterinary Journal* 35: 522–523
 20. Van Amstel S R, Van Vuuren S, Tutt C L C 1995 Digital dermatitis: report of an outbreak. *Journal of the South African Veterinary Association* 66: 177–181
 21. Walker R L, Read D H, Loretz K J, Nordhausen R W 1995 Spirochaetes isolated from dairy cattle with papillomatous digital dermatitis and interdigital dermatitis. *Veterinary Microbiology* 47: 343–355
 22. Weaver A D 1988 Cattle foot problems. Part 1: introduction and interdigital skin disease. *Agri Practice* 9: 34–38
 23. Weaver A D 1992 Bovine digital papillomatosis. *Proceedings of the 7th International Symposium on Diseases of the Ruminant Digit, Copenhagen*: 122
 24. Weaver A D 1994 Digital papillomatosis and digital dermatitis in cattle. *Veterinary Annual* 34: 20–27