

Rectal prolapse associated with a healed pelvic fracture in a pregnant free-ranging African black rhinoceros (*Diceros bicornis*). Part 2: surgery and necropsy

A Olivier^a, E Lane^b, D H Volkmann^c, M Hofmeyr^d and G F Stegmann^a

ABSTRACT

The oedematous and traumatised protruding section of the rectal tissue of an adult free-ranging female African black rhinoceros (*Diceros bicornis*) was surgically amputated. Immediately before completion of surgery, the rhinoceros died of anaesthetic-related cardiac arrest. At necropsy a deformed pelvis and sacrum associated with a healed fracture of the left ileal wing were noted. New bone formation in and around the left ventral sacral foramina may have resulted in neuropathy of particularly the 3rd and 4th left ventral sacral nerves, which (in the horse) supply the majority of the nerve fibres innervating the caudal rectum and anus. The cause of the injury is not known, although back injuries, presumably sustained during mating by bulls, have been recorded in white rhinoceros. An encounter with elephants could also have been responsible for the injury in this case.

Key words: African black rhinoceros, *Diceros bicornis*, pathology, pelvic fracture, rectal prolapse.

Olivier A, Lane E, Volkmann D H, Hofmeyr M, Stegmann G F Rectal prolapse associated with a healed pelvic fracture in a pregnant free-ranging African black rhinoceros (*Diceros bicornis*). Part 2: surgery and necropsy. *Journal of the South African Veterinary Association* (2001) 72(4): 242–244 (En.). Department of Companion Animal Clinical Studies, Faculty of Veterinary Science, University of Pretoria, Private Bag X04, 0110 South Africa.

INTRODUCTION

Anaesthesia resulting in the death of a free-ranging black rhinoceros (*Diceros bicornis*) is described in the first part of this case report¹. Surgery undertaken to correct a rectal prolapse and necropsy findings are described in Part 2.

EXAMINATION AND TREATMENT

Initial examination of the rhinoceros cow revealed a rectal prolapse with severe oedema and partial necrosis of the exposed tissues (Fig. 1). After liberal lubrication, with acriflavine-glycerine, the prolapsed tissues were reduced and held in position for 20 minutes. Transrectal examination revealed that she was pregnant with a large, live foetus. She was not considered to be near parturition as her udder was still completely dry. The animal was in good condition, suggesting that she had not been suffering from any chronic debilitating disease. Following

the usual protocol for immobilisation of black rhinoceros (see Part 1), the animal was treated with a long-acting penicillin (9 g procaine penicillin and 7 g benzathine penicillin, Lentrax, Rhône-Poulenc) and a non-steroidal anti-inflammatory drug (1 g flunixin meglumine; Finadyne, Schering-Plough).

Following the reduction of the prolapse, the rhinoceros was moved into a boma. The increased abdominal pressure brought about by the off-loading of the immobilised, recumbent animal caused the rectum to prolapse again.

The exposed tissues were cleaned and reduced. In order to keep the rectum in place, a purse-string suture was placed around the anal sphincter, using umbilical tape. Caudal epidural anaesthesia was attempted to reduce straining after reversal of the immobilising agent. Darkness set in and every effort was made to correctly identify the appropriate site for epidural puncture by palpation. Unexpectedly, this animal had a very wide intervertebral space of 4 cm at the tail root. No suction was noticed as the needle was advanced into the presumed epidural space and no cerebrospinal fluid escaped from the needle before the injection of 8 ml 2 % lignocaine HCl. Muscle tone in the tail could not be used to judge the

success or failure of this procedure because the animal was immobilised. Anaesthesia was reversed without complications and for at least 40 minutes following recovery the rectum remained in place.

By the following morning the rectum had prolapsed again and there was no sign of the purse-string suture around the anus. Seventy-two hours after the initial immobilisation the rhinoceros was again immobilised, initially in a standing position, for clinical and transrectal examination. An approximately 20 cm Type 1³ prolapse of the rectal tissue, with the mucosal and submucosal layers severely traumatised and oedematous, was confirmed. The anal sphincter tone was extremely poor, and the muscles of the tail flaccid. She was anaesthetised, went down in a sternal position and was placed on inhalation anaesthesia (Part 1). During surgery, the prolapsed tissue was resected circumferentially and anastomosed in a 2-layer fashion with no. 2 chromic catgut using a simple interrupted pattern, followed by a simple continuous pattern



Fig. 1: Traumatised rectal mucosa of prolapsed rectum.

^aDepartment of Companion Animal Clinical Studies, Faculty of Veterinary Science, University of Pretoria, Private Bag X04, 0110 South Africa.

^bDepartment of Production Animal Studies, Faculty of Veterinary Science, University of Pretoria, Private bag X04, 0110 South Africa.

^cDepartment of Clinical Science, College of Veterinary Medicine, Cornell University, Ithaca, NY 14853, USA.

^dGame Capture and Veterinary Department, Kruger National Park, PO Box 122 Skukuza, 1350 South Africa.

Received: April 2001. Accepted: September 2001.

using 2/0 polyglactin 910 (Vicryl, Ethicon), interrupted 4 times³. Approximately a fifth of the prolapsed tissue circumference was resected and anastomosed sequentially. The rectal arteries and veins were clamped with haemostats and tied off as they were found, but there was nevertheless a loss of approximately 3 l blood.

Immediately before completion of the amputation the rhinoceros died as result of cardiac failure despite repeated resuscitation attempts (Part 1). On further examination of the pelvis it became evident that the left tuber sacrale was not in its normal position, but displaced caudomedially, and that the caudal part of the sacrum and cranial portion of the coccygeal vertebrae were asymmetrical and distorted. The carcass was transported to the Faculty of Veterinary Science, Onderstepoort on the same day and kept in a refrigerated (4 °C) room overnight. A necropsy was performed the following day.

NECROPSY FINDINGS

The rhinoceros was pregnant and in reasonable body condition, showing mild *post mortem* autolysis. Apart from marked acute diffuse pulmonary congestion (particularly the left lung lobes), and the presence of a female foetus (30.8 kg) in the uterus, significant lesions were restricted to the pelvis and perineum. The distal portion (± 25 cm) of the rectum was moderately congested and oedematous, but the sutures associated with the partial anastomosis were intact. Extensive irregular submucosal haemorrhage was present proximal to the suture ring. Extensive shallow ulcers were present on the anal mucocutaneous junction (2–10 mm diameter). Histologically, mild subacute perivascular vaginitis was present as evidenced by the presence of lymphoplasmacytic cell cuffs around the blood vessels in the muscular layer of the vagina. No specific cause of cardiopulmonary arrest during anaesthesia could be determined.

In addition, the left iliac crest was positioned further caudodorsally than the right. The pelvis, caudal lumbar vertebrae, sacrum and tail were removed *in toto*, cleaned of excess soft tissue and radiographed. Accurate radiological evaluation of the partially cleaned pelvis was hampered by remaining pieces of soft tissue still adhering to the bones, causing many confusing soft tissue radiopacities. Radiologically, the right sacral tuberosity was in the correct anatomical position, whereas the left was malformed and displaced caudally and sagittally, in close apposition to the sacral dorsal spinous processes. The caudal sacral ver-

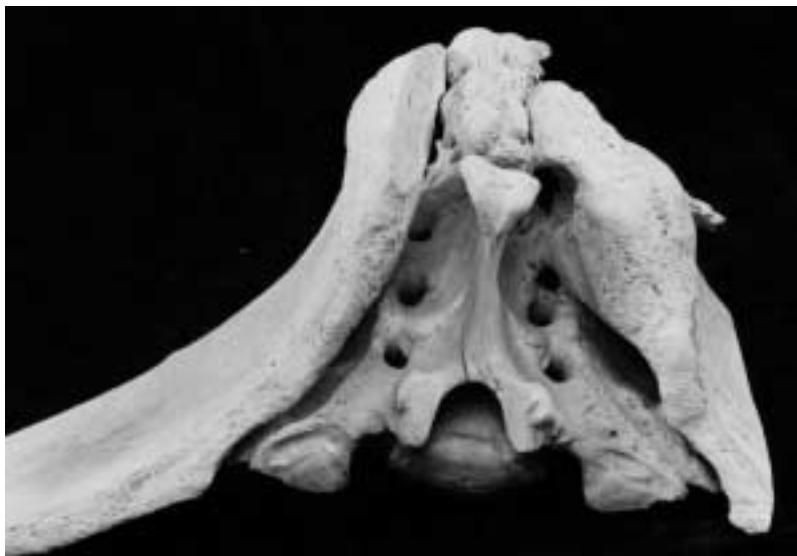


Fig. 2: **Craniodorsal view of macerated sacrum and pelvis showing pelvic asymmetry, the healed fracture of the left ilial wing, bony fusion of the left sacral tuberosity with the dorsal spinous processes of the 2nd, 3rd and 4th sacral vertebrae and bony fusion of the ventral left aspect of the wing of the ilium with the left lateral crest of the 3rd sacral vertebra.** (The dorsalmost aspect of the right tuber sacrale was removed during the maceration procedure).

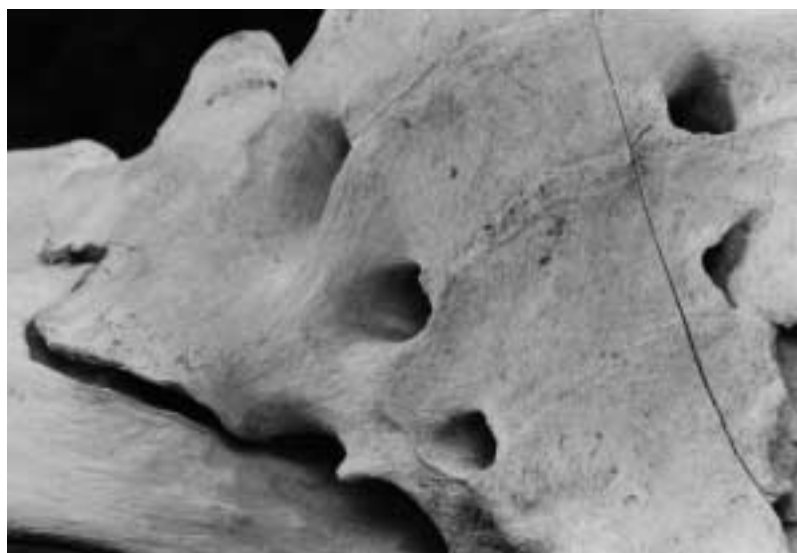


Fig. 3: **Ventral view of the sacrum showing narrowing of the left 3rd and 4th ventral sacral foramina.**

tebrae and their dorsal spinous processes were deviated to the left and the 2nd, 3rd and 4th sacral dorsal spinous processes were opposed and appeared partially fused. The left 3rd and 4th pelvic sacral intervertebral foramina were difficult to differentiate. The final radiological diagnosis was a healed left ileal wing fracture with caudomedially displaced tuber sacrale, healed caudal sacral and coccygeal vertebral fractures and caudal sacral deviation to the left.

After the pelvic and tail bones were completely cleaned, bony fusion between the left sacral tuber and the cranial dorsal spines of the sacrum was found, as well as fusion of the ventromedial aspect of the left sacral tuber and the left-lateral aspect of the 3rd and 4th sacral vertebral laminae. The ventral foramina of the left

3rd and 4th ventral sacral vertebrae were deformed and narrowed by new bone formation; and the caudal sacrum was deflected towards the left. (Figs 2, 3). Extensive bony deformities of the tail bones were also present.

DISCUSSION

The rectal prolapse amputation was performed as described in the horse³, resecting 1/5 of the diameter of the compromised tissue at a time, directly followed by anastomosis of the resected portion. This procedure was lengthy owing to the presence of numerous large rectal and anal vessels that required ligation. The surgery was performed in a boma and electro-coagulation facilities were not available. Although this might have hastened the procedure, the diame-

ters of most of the vessels were too large for electro-coagulation. Immediate resection of all tissues followed by ligation of vessels may have shortened surgical time. This option was not pursued, as the vessels tended to retract cranially and searching for them after resection would most likely have prolonged the surgical time rather than shortened it.

At the time of initial examination of the cow, when the poor tail and anal tone were noted, these deficits were assumed to be the result of the immobilising agents. While the exact cause of the neurological deficit to the anus and caudal rectum and resulting rectal prolapse is not clear, it seems likely that the new bone deposition in the pelvis caused pressure on the 3rd and 4th sacral nerves. Most of the fibres of these nerves in the horse form the pudendal, perineal and caudal rectal nerves, of which the last innervates the coccygeus, levator ani and external sphincter ani muscles, the terminal part of the rectum and the lateroventral aspect of the anus and peri-anal skin of the horse². Partial amputation of the prolapsed rectum would probably have been of temporary value if the rhinoceros had survived, since the nerve damage was not treatable. The pelvic cavity of the rhino was lined by thick fibrous connective tissue, obscuring the pudendal nerve, which could therefore not be located or examined histopathologically.

The field guard who had tracked this animal stated that the cow had had a wound on her escutcheon some months

before the rectal prolapse developed. She also did not curl her tail over the croup as is characteristic of the initial fleeing behaviour of rhinoceros.

Most mammals have increased plasma oestrogen and/or relaxin concentrations for a few weeks preceding parturition⁴, and this was considered to be a factor that might have contributed to the amplification of pelvic muscle and ligament laxity, resulting in the rectal prolapse. The birth weight of a black rhinoceros calf is approximately 35–40 kg⁵. This cow's pregnancy was thus far advanced, but probably at least 30 days pre-term, as her udder was still completely dry. Increased intra-abdominal pressure brought about by the rapidly expanding uterus, rather than endocrine factors, are thus more likely to have precipitated the prolapse through the compromised anal sphincter.

The cause of the bony lesions found in the pelvic region of this animal is not known. Back injuries, thought to be caused by aggressive mating behaviour of males, have been described in white rhinoceros cows (*Ceratotherium simum*) in South Africa¹. While the history of the wound in her perineal area suggests such a cause for the lesions, the trauma may have been inflicted while she was already pregnant. Forced mating attempts amongst free-living rhinoceros have not been documented, but it is possible that elephants could have caused her injuries. Some months earlier a number of white rhinoceros were killed by young rogue male elephants in the same national park

(G van Dyk, field ecologist, Pilanesberg National Park, pers. comm., 2001).

ACKNOWLEDGEMENTS

We thank the staff of Pilanesberg National Park for their assistance during the surgery, particularly Mr Gus van Dyk, field ecologist of Pilanesberg National Park for initiating the investigation and providing photographs, and the technical staff at the Departments of Anatomy and Production Animal Studies, Faculty of Veterinary Science, for cleaning the bones and processing histopathological specimens, respectively.

REFERENCES

1. Buys D 1999 Survey: white rhinos on private land. In *Proceedings of a workshop on conservation of African rhinos on private land through utilization*, Onderstepoort, South Africa, 8–9 October 1999: 1–7
2. Delman H D, McClure R C 1975 The equine nervous system. In Getty R (ed.) *Sisson and Grossman's The anatomy of the domestic animals*. W B Saunders, Philadelphia: 633–702
3. Freeman D E 1999 Rectum and anus. In Auer J A, Stick J A (eds) *Equine surgery* (2nd edn). W B Saunders, Philadelphia: 286–293
4. Jainudeen M R and Hafez E S E 2000 Gestation, prenatal physiology and parturition. In Hafez E S E, Hafez B (eds) *Reproduction in farm animals* (7th edn). Lippincott Williams and Wilkins, New York: 140–155
5. Skinner J D, Smithers R H N 1990 *The mammals of the southern African subregion* (2nd edn). University of Pretoria, Pretoria
6. Stegmann G F, Hofmeyr M, Olivier A, Lane E, Volkman D H 2001 Rectal prolapse associated with a healed pelvic fracture in a pregnant free-ranging African black rhinoceros (*Diceros bicornis*). Part 1: anaesthesia. *Journal of the South African Veterinary Association* 72: 239–241