

## Induction of photosensitivity in sheep with *Erodium moschatum* (L.) L'Hérit

J C Stroebel<sup>a</sup>

### ABSTRACT

*Erodium moschatum* is an exotic weed in the southern and southwestern coastal areas of the Western Cape Province (WCP), South Africa. It has been suspected as the cause of photosensitivity in sheep. However, attempts to induce photosensitivity by dosing it to sheep have thus far been unsuccessful. During August 1999, 2 sheep suffering from severe photosensitivity were presented for clinical examination to the Western Cape Provincial Veterinary Laboratory (WCPVL). One sheep was sacrificed for autopsy. Except for skin lesions associated with photosensitivity, no icterus or other lesions were present. Histopathological examination of affected skin revealed epidermal necrosis while the liver had no microscopic lesions. It was therefore concluded that the sheep might have been suffering from primary photosensitivity. The farm from which the sheep came, situated in the Malmesbury district, WCP, was visited to determine the source of the photodynamic agent. The flock from which the sheep originated had been grazing in a camp where *E. moschatum* was growing abundantly and had been heavily grazed. Some remaining *Erodium* in the camp was collected, pulped and dosed over a period of 7 days to an adult sheep. Another sheep was dosed simultaneously with *Erodium* growing on the premises of the WCPVL. Both sheep developed mild photosensitivity, which was confirmed by histopathological examination of skin biopsies. It was concluded that *E. moschatum* can induce photosensitivity (probably the primary type) in sheep if ingested in large quantities.

**Key words:** *Erodium moschatum*, photosensitisation, photosensitivity, sheep.

Stroebel J C Induction of photosensitivity in sheep with *Erodium moschatum* (L.) L'Hérit. *Journal of the South African Veterinary Association* (2002) 73(2): 57–61 (En.). Western Cape Provincial Veterinary Laboratory, Private Bag X5020, Stellenbosch, 7599 South Africa.

### INTRODUCTION

Animals are considered photosensitive if they develop dermatitis of unpigmented skin that is not protected by fleece or hair coat when exposed to sufficient solar radiation<sup>10</sup>. The dermatitis, which is characterised by erythema, followed by oedema, exudation and extensive necrosis of the skin, is due to the activation by ultraviolet or visible light of certain wavelengths of fluorescent chemical compounds (photodynamic agents) that have become bound to dermal cells<sup>5,10</sup>. Activated photodynamic agents cause tissue damage, either directly or indirectly, by the formation of reactive oxygen-free radicals<sup>10</sup>.

Primary photosensitisation is caused by direct interaction of ingested, percutaneously absorbed, or administered photodynamic agents with sunlight while the liver is normal but incapable of detoxifying or excreting the agent. Photodynamic agents (also known as phototoxins) can occur naturally in certain plants, inducing photosensitivity when these plants are ingested or come into contact with unpro-

tected skin. In the latter case the phototoxins are absorbed by the skin and cause localised photosensitivity (phytophot-contact dermatitis). Certain drugs such as euflavine, sulfonamides, tetracyclines and phenothiazine can also cause primary photosensitivity<sup>4,10</sup>. Rarely, photodynamic agents may also be produced by aberrant endogenous metabolism (e.g. in congenital porphyria in cattle)<sup>5</sup>.

Secondary, or hepatogenous, photosensitivity, which develops only in herbivores, occurs secondarily to hepatic pathology, causing non-haemolytic intra-hepatic cholestasis of more than a few days' duration<sup>5</sup>. The damaged liver's capacity to excrete the photodynamic degradation product of chlorophyll, phylloerythrin, which is normally excreted together with bile pigments in the bile, is diminished. The result is that phylloerythrin accumulates in tissues, including the skin<sup>5,10</sup>. Icterus is typically associated with hepatogenous photosensitivity, but the latter may occur in its absence<sup>4,5</sup>.

In South Africa the plant *Hypericum perforatum* (St John's wort), which is notorious for causing primary photo-

sensitivity, occurs abundantly at certain localities in the Western Cape Province<sup>1</sup>, but has never been implicated in local outbreaks of photosensitivity<sup>4</sup>. However, ingestion of *Hypericum aethiopicum* (also known as St John's wort), *Ammi majus* (bishop's weed, lace flower, *kantblom*) and the seeds of *Fagopyrum esculentum* (buckwheat), have been incriminated in incidents of naturally occurring primary photosensitivity in sheep and/or cattle<sup>4,7</sup>. *H. aethiopicum* and *F. esculentum* respectively contain the photodynamic agents hypericine and fagopyrin (both pigments of the helianthone family), while *A. majus* contains a furocoumarin<sup>10</sup>. Furocoumarins are photodynamic agents capable of causing photosensitivity upon contact or after being ingested. They differ from the helianthone pigments by additionally inducing corneal oedema and keratoconjunctivitis<sup>10</sup>. The plant *Peucedanum galbanum* (blister[ing] bush, *bergseldery*<sup>9</sup>) was implicated in an incident where a large proportion of a flock of sheep developed severe keratitis leading to blindness after they had ingested cut plant material from which a volatile oil had previously been extracted (F E van Niekerk, formerly University of Stellenbosch, pers. comm., 2002). The plant is known to blister the skin of humans on contact. This blistering effect varies with the weather<sup>11</sup>. Furocoumarins occur, or are generated, in both cultivated and wild members of the families Apiaceae (which includes *A. majus* and *P. galbanum*<sup>9</sup>), Rutaceae, Fabaceae, Moraceae and Orchidaceae occurring in southern Africa, but these plants (with the exception of the 2 species mentioned above) have never been associated with photosensitisation of domestic animals in South Africa<sup>4</sup>. Compared to secondary photosensitivity, which in South Africa may be induced by several hepatotoxic plants, 2 fungi and an alga, primary photosensitivity rarely occurs<sup>4</sup>.

*Erodium moschatum* (of the family Geraniaceae) is readily ingested by sheep, goats and ostriches<sup>1</sup>. The plant has for some years been suspected of causing photosensitivity in sheep, especially when heavily grazed. However, attempts to induce photosensitivity by dosing it to sheep were unsuccessful (D J Schneider,

<sup>a</sup>Western Cape Provincial Veterinary Laboratory, Private Bag X5020, Stellenbosch, 7599 South Africa.  
E-mail: jacobs@wcpe.agric.za  
Received: February 2001. Accepted: May 2002.

formerly Western Cape Provincial Veterinary Laboratory (WCPVL), pers. comm., 2002).

This paper describes a natural outbreak of photosensitivity in a flock of sheep, which was attributed to the ingestion of *E. moschatum*, and confirmation of its toxicity in a dosing trial.

### NATURAL OUTBREAK

Early in August 1999, 2 adult Merino ewes suffering from severe photosensitivity were presented to WCPVL for clinical examination. The sheep originated from a farm near Riebeeck-Wes in the Malmesbury district of the Western Cape Province, South Africa (33°18'S, 18°51'E). The flock had recently been shorn. Over a period of about 2 weeks, 10 of the flock of about 350 sheep were affected, one of which died.

Clinically, the sheep had purulent crusts on their nasal planes and other woolless areas on their faces, vulvas and coronets. (Fig. 1) Their ears were erythematous, but not swollen. Serum samples were collected for the determination of liver-specific enzyme activities. One ewe (Sheep 1) was sacrificed for autopsy with an overdose of pentobarbitone sodium (Eutha-naze, Centaur) intravenously. Tissues for histopathology were collected, fixed in 10 % buffered formol-saline, and processed by standard methods. Sections were cut at 5 µm and stained with haematoxylin and eosin (H&E) for microscopic examination.

A provisional diagnosis of photosensitivity was made and the farm was visited.

### FIELD INVESTIGATION

The flock had been grazing in a camp where medics (annual *Medicago* spp.) were established. An abundance of flowering *E. moschatum* growing between the medics was also noticed. Both plants were heavily grazed. No remedies that could cause photosensitivity had recently been given to the sheep.

Some of the remaining *E. moschatum* in the camp were collected. Specimens of the plant were sent to the National Botanical Institute, Kirstenbosch Research Centre, for identification.

### EXPERIMENTAL PHOTOSENSITISATION

The remainder of the fresh plant material was pulped in a blender and dosed orally with a stomach tube over a period of 5 days to an adult sheep (Sheep 3) from a flock of 70 unshorn South African Mutton Merinos grazing on the premises of the WCPVL at Stellenbosch. A 2nd sheep (Sheep 4) from the flock was dosed with *Erodium* growing on the same premises (Table 1)

Table 1: Daily quantities of *Erodium moschatum* dosed to experimental sheep.

Day	Sheep (ID no.)					
	Sheep 3 (27/97)			Sheep 4 (30/94)		
	WM* (kg)	DM** (g)	DM/kg BM* (g)	WM (kg)	DM (g)	DM/kg BM (kg)
	Body mass: 65 kg (dosed with plants from farm)			Body mass: 85 kg (dosed with plants from laboratory)		
1	0.80	124	1.9	1.36	211	2.5
2	0.80	124	1.9	1.37	212	2.5
3	2.65	411	6.3	2.60	403	4.7
4	2.85	442	6.3	2.85	442	4.8
5	~1.67	~259	~4.0	2.46	381	4.5
Total	~8.77	~1360	~20.9	10.64	1649	19.4
Mean	~1.75	~272	~4.2	2.13	330	3.9

\*Wet mass; BM, body mass.

\*\*Dry matter – calculated as 15.5 % of the wet mass of fresh flowering plants about 2 months after the dosing trail, when the plants were still flowering but were more mature. It might therefore have been somewhat lower at the time of dosing.

The amount of plant material dosed was determined by 2 factors: first, the volume of water required to blend it into a slurry thin enough to pass through the stomach tube (12 mm internal diameter), and second, the volume of slurry that could be dosed safely to each sheep. Owing to the large volumes, the daily doses (7–8 l) were divided into 2 equal parts. These were dosed at an interval of about 6 hours in the mornings and afternoons (Table 1). Each day's doses were prepared the previous day. Blended and unblended plant material was kept in a refrigerator until needed.

For the duration of the dosing period (5 days), plus an additional 12 days, the sheep were kept in a small paddock with Kikuyu grass where they had free access to water and where they were maximally exposed to the sun. They were inspected daily for signs of photosensitivity. On day 11 of the trial, a skin biopsy was performed under local anaesthesia (Lignocaine 2 %, Janssen AH). Samples were collected from the affected lateral nostril wings and lips of Sheep 4 and processed routinely for histopathological examination. Blood samples were taken from both sheep as well as from 3 adult control animals on day 14. Serum activities of gamma glutamyl transferase (GGT) and aspartate aminotransferase (AST) were determined. The control animals were randomly selected from the laboratory's flock, which had been grazing in a camp with natural grass and minimal shade during the day. Except for having received a routine dose of cobalt chloride (to prevent cobalt deficiency) on day 8 of the trial, these sheep were not treated differently from the 2 experimental sheep.

### PHOTOTOXIC ACTIVITY

Samples of *E. moschatum* growing on the laboratory's premises was sent to the Faculty of Veterinary Science, University

of Pretoria, for a phototoxin assay as described by Rowe *et al.*<sup>6</sup> (The presence of furocoumarins in plants suspected to be involved in primary photosensitisation can be investigated by this test in which the growth of *Candida albicans* on agar plates is inhibited when suspect plant material is applied to the agar surface and exposed to ultraviolet light in a certain range of wavelengths) The test was repeated twice using different parts of the plants. Samples were obtained from plants that were at the reproductive stage as well as those that were actively growing (with and without flowers or fruit respectively).

### RESULTS

#### Plant identification and description

The plant collected on the farm was identified as *E. moschatum* (commonly referred to as musk heron's bill) – an annual or biennial, erect to procumbent, aromatic herb belonging to the family Geraniaceae<sup>1,3,8</sup> (Fig. 2). The common name refers to a musk-like odour when being crushed<sup>1</sup>, and also to its young fruit which has elongated styles, loosely fused into columns, each style resembling a heron's bill<sup>3</sup>. The plant, which reaches a height of about 30 cm, has pinnately compound leaves with serrated leaflets, and inflorescences consisting of 5–13 violet to pink flowers each<sup>3,8</sup>. After fertilisation the 5-locular ovaries of the flowers develop into dehiscent fruit, each consisting of 5 segments known as mericarps. (J Beyers, National Botanical Institute, pers. comm., 2001). When the fruits mature, the styles break away from each other, twisting into corkscrew-like helices. This process causes the fruit to split and release the mericarps, each containing a single seed<sup>3,8</sup>. The helical tails (*i.e.* styles) of the freed mericarps are reminiscent of very long, twisted human nails – hence the

Afrikaans name *turknael* ('Turkish nail') (Fig. 3). In South Africa, flowering occurs from June to December, peaking in July, August and September<sup>8</sup>.

*E. moschatum* is indigenous to Europe and Asia, but has been present in South Africa for more than a century<sup>1,8</sup>. It now occurs as a naturalised weed in the temperate southern and southwestern coastal areas of the Western Cape Province, which are year-round and winter rainfall areas, respectively. The species is commonly found on disturbed soil, e.g. along roadsides, in orchards, vineyards, cultivated fields and gardens, but it also thrives in open veld (i.e. grassland)<sup>1,3,8</sup>.

#### Natural outbreak: autopsy, histopathological findings and enzyme activities

Except for the skin lesions, gross pathological examination of Sheep 1 from the natural outbreak indicated no obvious lesions of the liver or other organs. There were also no signs of icterus.

Histopathological examination of affected skin revealed severe epidermal necrosis with serocellular crust formation and severe inflammatory changes in the dermis (Fig. 4). The liver, however, appeared normal.

Serum enzyme activities of GGT and AST of the affected sheep were both higher than those of 3 apparently healthy sheep from the flock kept at the WCPVL (Table 2).

The remaining ewe (Sheep 2) from the natural outbreak recovered completely after being kept out of the sun for 10 days in a hospital shed. All crusts were shed, leaving pale pink areas of regenerated epidermis where they had been attached. It was evident that the skin of her back had also been affected. Large plaques of dried exudate, which had been lifted off the skin by growing wool, could be seen and felt in the wool covering her back.

#### Dosing trial: clinical signs, histopathological findings and enzyme activities

From days 1–5 the sheep (Sheep 3 and 4) dosed with *E. moschatum* material did not eat the available grass in their paddock – which was attributed to the relatively large volumes of plant slurry dosed daily. Both sheep developed signs of mild solar dermatitis without icterus. On day 8 of the trial, Sheep 3 (dosed with *Erodium* collected on the farm) showed erythema with crust formation on the nasal plane and ears (Figs 5, 6). This developed in spite of overcast conditions and rainy weather from days 5–7. On day 10, mild coronitis was visible. On day 11, Sheep 4 also showed erythema with crustiness of

Table 2: Serum activities of GGT and AST in field cases of photosensitivity in sheep.

Sheep (ID no.)	GGT (IU/l)	AST (IU/l)
Sheep 1 (2093)	111	327
Sheep 2 (5034)	138	281
Control 1	79	162
Control 2	98	202
Control 3	51	132

its nose. By day 17, the erythema of the noses and ears of both sheep had disappeared and the only indication of previous skin damage was scaliness of the nasal planes and dorsal parts of the ears. None of the control animals developed noticeable lesions associated with photosensitivity.

On histopathological examination moderate necrotic dermatitis was seen. This was characterised by mostly superficial necrosis of the epidermis with serocellular crust formation and mild inflammation of the dermis (Figs 6, 7).

The liver enzyme activities of Sheep 3 were similar to those of the controls. However, the enzyme levels of Sheep 4 were markedly raised (Table 3).

#### Phototoxic activity

The phototoxin assay was negative for the presence of phototoxins.

#### DISCUSSION

Based on the lack of gross or microscopic indications of liver damage, including icterus, in either sheep from the natural outbreak, it was initially concluded that the photosensitivity they had been suffering from was most probably primary in origin. However, hepatogenous photosensitivity cannot be excluded unless adequate liver-function tests are performed<sup>5</sup>. The increased AST activities in the 2 sheep could not be explained satisfactorily in the absence of obvious liver damage or gross muscle lesions, because AST is most abundant in liver and muscle cells<sup>2</sup>. The increased activity of GGT might have been caused by bile stasis, which is known to cause increased serum GGT activity<sup>2</sup>. Bile stasis, again, could have been caused by anorexia, which in turn might have resulted from the affected animals' painful, inflamed lips, which had prevented them from grazing. Because of the unexplained increased activity of AST, which could have been caused by liver damage, hepatogenous photosensitivity being involved in the field outbreak could not be excluded beyond doubt.

The sheep in the dosing trial developed dermal and histopathological lesions

Table 3: Serum activities of GGT and AST in experimental sheep.

Sheep (ID no.)	GGT (IU/l)	AST (IU/l)
Sheep 3 (27/97)	49	150
Sheep 4 (30/94)	226	1852
Control 1	62	111
Control 2	65	123
Control 3	51	143

that are typical of photosensitivity. Although the lesions of these sheep were much milder than those observed in the field outbreak, the lesions were similar. The essentially normal serum activities of liver enzymes of Sheep 3 compared with the control sheep, suggests the absence of hepatic damage in this animal. Thus, photosensitisation, at least in this case, could have been primary in origin. The high GGT activity of Sheep 4 (as in the sheep of the field outbreak) could be related to bile stasis due to anorexia, but in this instance the latter was possibly caused by pain suffered after the lip biopsy. The raised AST activities might have been caused by handling and restraint of the animal as well as injury inflicted to lip muscles when the biopsy was taken. (AST is also considered a diagnostic enzyme for muscle tissue damage<sup>2</sup>.) However, considering the small number of sheep used in the dosing trial, these results do not convincingly exclude liver damage as the cause of photosensitivity in these animals – even if liver damage was not observed grossly or microscopically.

Photosensitivity was induced with plant material from 2 localities that are about 60 km apart, suggesting that the plant could be toxic under a variety of conditions.

During September, about 1 month after the trial, 2 adult sheep were fenced off in an area on the laboratory's premises where only *E. moschatum* grew and where they were exposed to the sun for most of the day. These plants were generally more mature (i.e. forming fruit and releasing mericarps) than those that had been used in the dosing experiment. The sheep ingested all the available plants within 7 days but did not develop clinical signs associated with photosensitivity. It therefore appears that the toxicity of *E. moschatum* can vary with the growth stage of the plant, actively growing plants being more toxic. This notion is further supported by information received from a farmer whose farm is situated further up the western coast, near Nieuwoudtville (31°20'S, 31°20'E), where it is much drier. According to him, signs of photo-

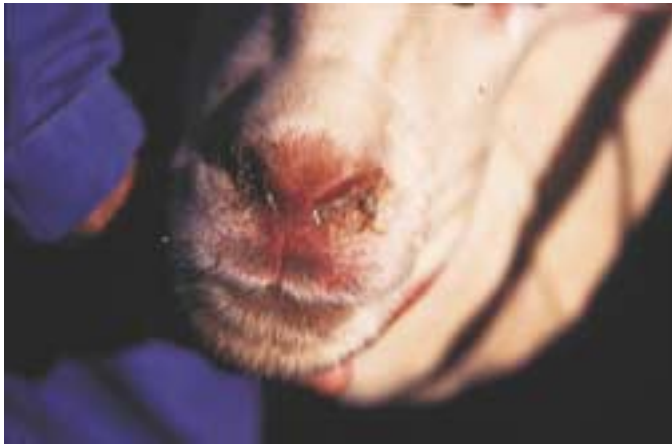

Fig. 1: Purulent crusts formed on the nasal plane of a sheep with suspected *Erodium moschatum* photosensitisation.



Fig. 2: *Erodium moschatum*.



Fig. 3: *Erodium moschatum*: mericarp.

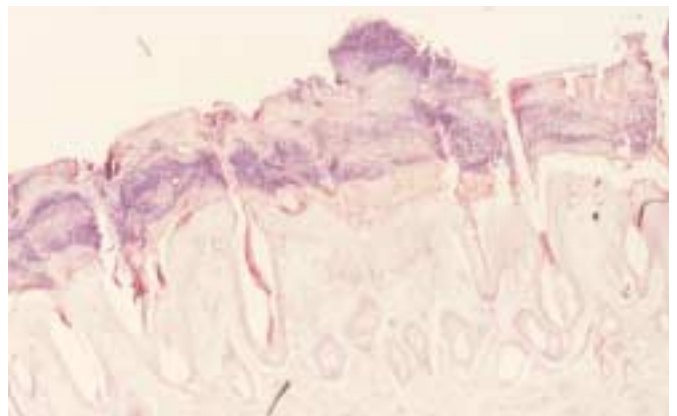


Fig. 4: Histological section of affected skin of a field case of suspected *Erodium moschatum* photosensitisation with severe necrotic dermatitis (H&E, x200).

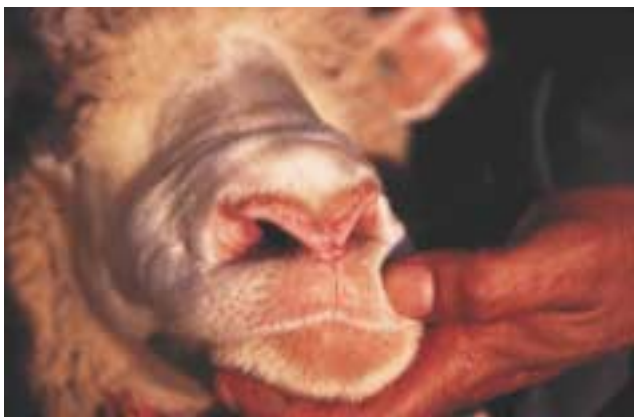

Fig. 5: Redness and crust formation of the nasal plane of an experimental case of *Erodium moschatum* photosensitisation.

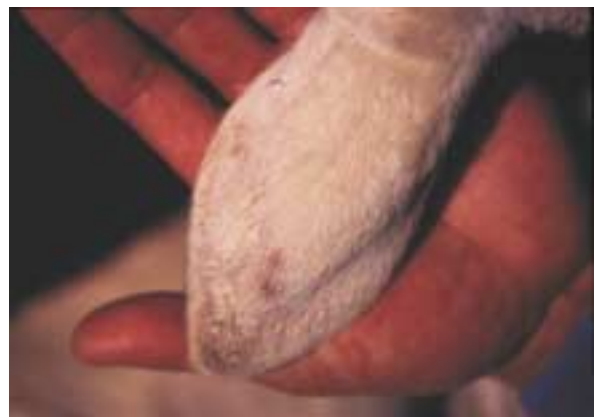
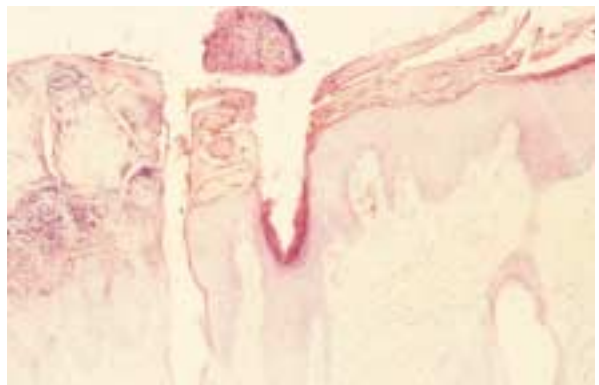
Fig. 6: Crust formation on the ear of an experimental case of *Erodium moschatum* photosensitisation.

Fig. 7: Histological section of affected skin of an experimental case of *Erodium moschatum* photosensitisation with moderate necrotic dermatitis (H&E, x200).



sensitivity among sheep appear annually in certain camps with young, non-flowering *E. moschatum* at the beginning of winter (April/May), when local pastures start to grow. As the pastures mature, the the clinical signs disappear (N MacGregor, pers. comm., 1999). The relationship between growth stage of the plant and its toxicity requires further investigation.

The photodynamic agent of *E. moschatum* is still unknown. Phototoxins known to be detected by the phototoxin assay used include furanocoumarins and alkaloids, phenolics, quinones, terpenoids, acetylenes, and their thiophene derivatives. Unfortunately, the assay does not detect all phototoxins, including hypericin and fagopyrin<sup>6</sup>.

In this experiment, photosensitivity, which was probably primary in origin, could be successfully induced in sheep by dosing them with relatively large amounts of fresh young growth of *E. moschatum*. The results indicate that *E. moschatum* could cause photosensitivity in sheep if ingested in large enough quantities. Farmers and veterinarians

should therefore be aware of the potential toxicity of this plant, as sheep readily ingest it, especially when other grazing is scarce.

#### ACKNOWLEDGEMENTS

I thank the following staff members of WCPVL for their invaluable technical assistance, without which this paper would not have been possible: Messrs P Slingers and C Jantjies, Ms B C Cloete and Ms R Pieterse. The contributions of Dr J Beyers of the Compton Herbarium, Kirstenbosch Research Centre, in identifying the plant and Dr J A Picard and her staff of the Department of Veterinary Tropical Diseases, University of Pretoria, for performing the phototoxic assay, are also much appreciated. The financial support of the Directorate Veterinary Services of the Western Cape Province is gratefully acknowledged.

#### REFERENCES

1. Bromilo C 1995 *Problem plants of South Africa*. Briza Publications, Pretoria
2. Duncan JR, Prasse K W 1986 *Veterinary laboratory medicine* (2nd edn). Iowa State University Press, Ames
3. Henderson M, Anderson J G 1966 *Common weeds in South Africa*. *Botanical Survey Memoir no. 37*. Department of Agricultural Tech-

- nical Services, Pretoria
4. Kellerman T S, Coetzer J A W, Naudé T W 1988 *Plant poisonings and mycotoxicoses of livestock in southern Africa*. Oxford University Press, Cape Town
5. Kelly W R 1993 The liver and biliary system. In Jubb K V F, Kennedy P C, Palmer N (eds) *Pathology of domestic animals*, vol. 2 (4th edn). Academic Press, San Diego
6. Rowe L D, Norman J O 1989 Detection of photosensitivity in plants specimens with primary photosensitization in livestock using a simple microbiological test. *Journal of Veterinary Diagnostic Investigation* 1: 269–270
7. Van Niekerk F A 1994 Suspected *Ammi majus* toxicity. *VetMed* Autumn 1994: 43
8. Venter H J T, Verhoeven R L 1990 The genus *Erodium* in southern Africa. *South African Journal of Botany* 56: 79–92
9. Wells M J, Balsinhas A A, Joffe H, Engelbrecht V M, Harding G, Stirton C H 1986 *A catalogue of problem plants in southern Africa incorporating the national weed list of southern Africa*. *Botanical Survey of South Africa, Memoir no. 53*. Department of Agriculture and Water Supply, Pretoria
10. Yager J A, Scott D W 1993 The skin and appendages. In Jubb K V F, Kennedy P C, Palmer N (eds) *Pathology of domestic animals*, vol. 1 (4th edn). Academic Press, San Diego
11. Watt J M, Breyer-Brandwijk M G 1962 *The medicinal and poisonous plants of southern and eastern Africa*. E & S Livingstone, Edinburgh