

Another human ear tick case

I should like to add another observation to the recent letter to the editor on the spinose ear tick¹. Our youngest daughter, then 13 years old, went on a riding holiday to the Eastern Cape. When she came back she complained about most unpleasant itching in one ear. We could not discover anything in the ear canal that would account for the painful itch, which was present sporadically. Some days later, when the itching was very painful again, I could

see the legs of what appeared to be a tick. I contacted our family doctor, who did not believe me, as he had never seen a tick in a patient's ear in all his years in urban practice. He asked me to bring the patient to his consulting room and was most surprised also to see the legs. He flushed the ear and a live engorged tick emerged, which was not further identified. According to the description of the symptoms described in the letter, it is likely to have

been the same type of tick, particularly as it was also associated with horses. The doctor prescribed an antibiotic against possible bacterial infection. The itching and pain disappeared and the recovery was uneventful.

Reference

1. Naudé T W, Heyne H, van der Merwe I R, Benic M J 2001 Spinose ear tick, *Otobius megnini* (Dugès, 1884) as the cause of an incident of painful otitis externa in humans. *Journal of the South African Veterinary Association* 72: 118-119

H F Huchzermeyer

PO Box 12499, Onderstepoort, 0110 South Africa

A congenital defect of the distal forelimb of a cat and of a dog

A sterilised, female calico domestic cat, weighing 4 kg, was presented to a private practitioner for examination. Her mother had produced her first and only litter, comprising 6 kittens, at the age of 3 years. Apart from this particular cat, all of the kittens appeared to be normal.

The cat presented appeared to have no problems apart from the structure of her right forelimb, which she did not use when walking. The distal portion of the forelimb appeared to be duplicated, and the tips of each of the 2 rays bore digits with claws. One small digit was present on the medial ray and 2 longer digits on the lateral ray. She used the other 3 legs for locomotion, and was able to jump through an open window, higher than 1 m off the ground. The elbow was fixed in a flexed position.

She was first examined by the reporting veterinarian at an age of 3 years, as she was ill, weak and unable to jump to even a small height. Either cystitis or an unknown urinary bladder complication was suspected, and she was treated with amoxicillin (Clamoxy RTU, Pfizer) parenterally and orally for 5 days. She was returned for re-examination less than a month later, as she was still struggling to jump and suffered from urinary and faecal incontinence. Initial improvement was observed after injecting her with 10 mg prednisolone (Kyron), and dispensing 5 mg prednisolone tablets (Be-tabs, Pharmaceutical Pty Ltd) and Extract of Green Lipped Mussel (Compass Distributors) at 125 mg per day. Her improvement lasted for 2 months, after which she deteriorated again, suffered from faecal and urinary incontinence, and was euthanased at the owner's request.

Photographs of the forelimb of the cat

(Fig. 1) and the X-ray image are presented here (Fig. 2). The duplicated lower portion of the right forelimb can be seen. An X-ray revealed that the radius and ulna had developed in such a way that they formed 2 complete compartments that were separated by skin to halfway up the shafts. The olecranon of the ulna had dislocated proximally and the bones involved in the joint were fused. The proximal shaft of the ulna had bent around the distal end of the humerus. The distal end of the ulna was deformed and the carpal bones were disrupted. Only the first digit was present at the distal end of the radial side of the forelimb, and digits 4 and 5 were present on the ulnar side. The proximal joints of the digits attached to the ulna were hyperflexed and the distal joints were hyperextended. The digit attached to the radius projected out straight.

A 4-year-old Boerboel bitch, born of registered parentage, was presented at the same veterinary practice and another apparent duplication of forelimb elements was observed. In this case, the

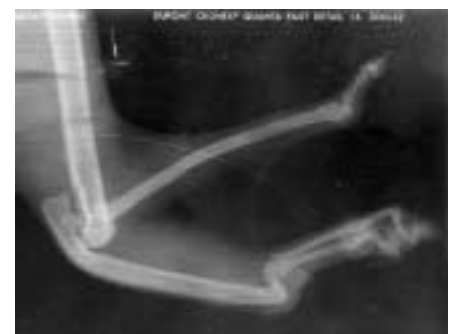

Fig 2: Lateral radiograph of the right forelimb of the cat. The radial component bears digit one and the ulnar component bears digits four and five.

digits of her left forepaw were deeply separated between the 3rd and 4th rays, and all 5 rays were visible externally (Fig. 3). The owners reported that she would shake this paw at first in the morning but would then walk and run quite normally.



Fig 1: Photograph of the right forelimb of the cat.

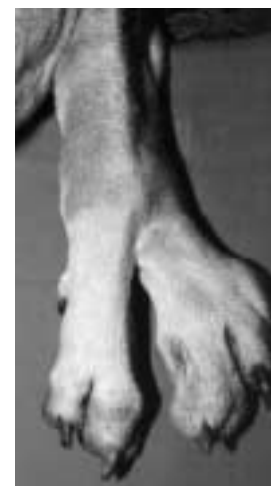

Fig 3: Photograph of the left forelimb of the dog.

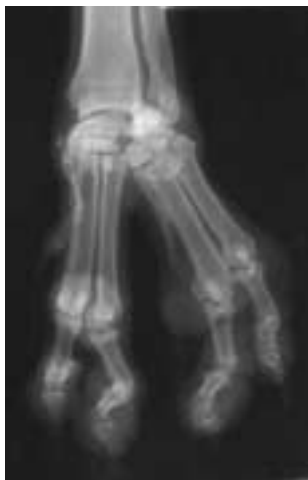

Fig 4: Lateral radiograph of the left forelimb of the dog. There is a deep cleft between digits 3 and 4, and a sixth digit along the axial side of digit 4.

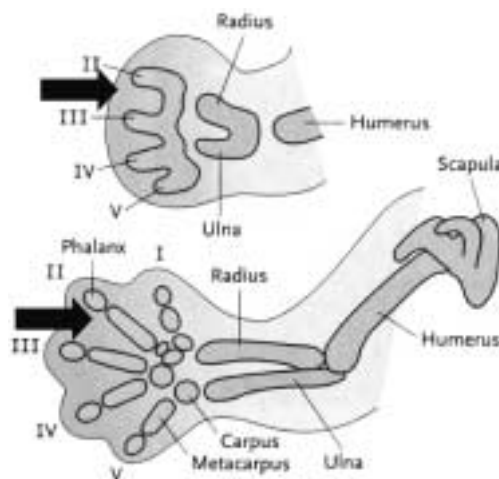


Fig. 5: Formation of the mammalian forelimb (adapted from Carlson B M 1999 *Human embryology & developmental biology*, 2nd edn. Mosby, Copyright Clearance Centre, Danvers, MA). A small nick in the apical ectodermal ridge (arrow in position for the cat), extending down into the underlying mesoderm, may result in separation of the radial and ulnar rays of the distal portion of the forelimb in the cat and failure of digits two and three to develop, or the separation of the digital rays 3 and 4 in the dog, in addition to polydactyly.

An X-ray of the forelimb revealed that metacarpals 3 and 4 were separated in a proximal direction up to the level of the carpometacarpal joint, and a 6th digit was visible subcutaneously on the axial side of digit 4 (Fig. 4). This patient was therefore also polydactylous.

Limb growth and patterning result from the molecular interactions between 2 tissue layers, the ectoderm (apical ectodermal ridge) and the underlying mesenchyme. There have been numerous reports of experimentally-induced and naturally-occurring limb duplications and the molecular basis of some of these duplications has been elucidated (ref. 1 and P Pietsch, Indiana University, Bloomington, pers. comm., 2001*). How-

*[Http://www.indiana.edu/~pietsch/cv.html](http://www.indiana.edu/~pietsch/cv.html)

ever, in the case of this cat and dog, it appears that the abnormality is the result of the bifurcation of the existing elements of the limb, and not a duplication of limb elements, and the suggestion is that the anomaly occurred as a result of in utero damage to a single limb. It is likely that this bifurcation did not occur at the initiation of the outgrowth of the limb bud, since this would have led to a full duplication of elements, but rather slightly later, that is after or during the specification of the ulnar and radial elements in the cat, or early in the establishment of the 5 digital rays in the dog. A possible scenario is that during the outgrowth of the limb bud at this early stage, there was a nick in the apical ectodermal ridge that healed with a cleft (Fig. 5). In the case of the cat, during the process of damage, digits 2 and 3

failed to develop. The two portions of the limb then continued to grow as separate compartments, and, although patterning and differentiation continued, the overall organisation and therefore functioning of the limb were severely compromised. Further evidence of in utero damage is that there are other abnormalities that may eventually have led to the death of the cat. In the case of the Boerboel, an additional digit was induced to develop along the axis of the digital rays, possibly as a result of initial damage that caused splitting off of components of a developing ray.

Reference

1. Pietsch P 1991 Effects of retinoic acid on the muscle patterns produced during forelimb regeneration in larval salamanders (*Amblyomma*). *Cytobios* 66: 41-61

G J Louw^a, S H Kidson^a and S J E M van Schouwenburg^b

^aDepartment of Human Biology, Faculty of Health Sciences, University of Cape Town, PO Observatory, Cape Town, 7924 South Africa

^bPrivate practitioner, Waterkloof Dierehospitaal, Bronkhorst Street, New Muckleneuk, Pretoria, 0181 South Africa