The spinal nerves that constitute the lumbosacral plexus and their distribution in the chinchilla

M A Martinez-Pereira[a*] and E M Rickes[b]

ABSTRACT

In this study, the spinal nerves that constitute the lumbosacral plexus (*plexus lumbosacrales*) (LSP) and its distribution in *Chinchilla lanigera* were investigated. Ten chinchillas (6 males and 4 females) were used in this research. The spinal nerves that constitute the LSP were dissected and the distribution of pelvic limb nerves originating from the plexus was examined. The iliohypogastric nerve arose from L_1 and L_2,, giving rise to the cranial and caudal nerves, and the ilioinguinal nerve arose from L_3. The other branch of L_3 gave rise to the genitofemoral nerve and 1 branch from L_4 gave rise to the lateral cutaneous femoral nerve. The trunk formed by the union of $L_{4–5}$ divided into medial (femoral nerve) and lateral branches (obturator nerve). It was found that the LSP was formed by all the ventral branches of L_4 at L_6 and S_1 at S_3. At the caudal part of the plexus, a thick branch, the ischiadic plexus, was formed by contributions from $L_{5–6}$ and S_1. This root gave rise to the nerve branches which were disseminated to the posterior limb (cranial and caudal gluteal nerves, caudal cutaneous femoral nerve and ischiadic nerve). The ischiadic nerve divided into the caudal cutaneous surae, lateral cutaneous surae, common fibular and tibial nerve. The pudendal nerve arose from $S_{1–2}$ and the other branch of S_2 and S_3 formed the rectal caudal nerve. The results showed that the origins and distribution of spinal nerves that constitute the LSP of chinchillas were similar to those of a few rodents and other mammals.

Keywords: anatomy, *Chinchilla lanigera,* lumbosacral plexus, pelvic limb innervation, posterior limb.

Martinez-Pereira M A, Rickes E M **The spinal nerves that constitute the lumbosacral plexus and their distribution in the chinchilla**. *Journal of the South African Veterinary Association* (2011) 82(3): 150–154 (En.). Neuroscience Post-graduate Program and Comparative Neurobiology Laboratory, Physiology Department, Health Basic Science Institute, Federal University of Rio Grande do Sul, Rua Sarmento Leite, 500, Porto Alegre, RS, Brazil, 90046-900.

INTRODUCTION

The order Rodentia includes approximately 40 % of described mammal species[2]. Among these, some are of great interest in commercial breeding, like the chinchilla (*Chinchilla lanigera,* Hystricomorpha, Chinchillidae)[6]. Owing to indiscriminate hunting throughout the 19th century these animals were considered extinct[23,24]. However, the unique characteristics of the coat (30 times softer than human hair and of high density, about 20 000 pili/cm^2) were the motive for the initial breeding of this species in captivity. Currently, the state of Rio Grande do Sul represents the largest breeder and exporter of chinchilla skins in Brazil, but the national market is growing, mainly in pet animals. Chinchillas are bred for the same purposes in other countries[30,31]. In spite of its commercial importance and its recent inclusion among animals bred as pets, there is a lack of studies related to its biology.

The spinal origins of the lumbosacral plexus (LSP) that supply the posterior limb have been studied in variety of mammals including the rat[1,11,22,35], mouse[12], guinea pig[13], rabbit [5,21,26], Brazilian rock cavy[25], agouti[29], porcupine[3,4], South American fur seal[9], dog[19,28] and cat[14,20]. In the chinchilla, the brachial plexus[10,18], the formation of the hepatic portal vein[7], the morphology of the digestive system[8] and the organisation, distribution and supply area of the middle cerebral artery[15] have been studied. However, to the author's knowledge this is the first study on the spinal origins and distribution of the areas innervated by the LSP in *Chinchilla lanigera.* The purpose of this study was to document the spinal nerves that constitute the LSP and supply the posterior limb in this species.

[a]Neuroscience Post-graduate Program and Comparative Neurobiology Laboratory, Physiology Department, Health Basic Science Institute, Federal University of Rio Grande do Sul, Rua Sarmento Leite, 500, Porto Alegre, RS, Brazil, 90046-900.

[b]Parasitology Post-graduate Programme, Biology Institute, Federal University of Pelotas, Rio Grande do Sul, Brazil.

*Author for correspondence.
E-mail: malconanato@yahoo.com.br

Received: May 2010. Accepted: June 2011.

MATERIALS AND METHODS

Ten chinchillas (6 males and 4 females) that were sacrificed at breeding farms in Pelotas city, Brazil, were used. The abdominal cavity was opened by an incision along the *linea alba* and dissection of the abdominal muscles. The pelvic symphysis was cut with rib cutters and the pelvic cavity was opened. The organs of the abdominal and pelvic cavities were removed without the spinal nerves constituting the LSP. The *quadratus lumborum, psoas minor* and *psoas major* muscles were dissected carefully. The ventral part of the lumbar and sacral vertebral bodies and the area from the last thoracic vertebra to the end of sacrum was completely exposed. The origins of spinal nerves that constitute the LSP and the supply of the nerve branches that originate in this plexus in both posterior limbs were examined. The best visualisation of the nerve structures was obtained with a solution of 30 % glacial acetic acid diluted in absolute ethanol for 30 minutes[33]. Subsequently, the dissections were fixed in 10 % formaldehyde aqueous solution and photographed. The terminology is according to the *Nomina anatomica veterinaria*[40].

RESULTS

Lumbosacral plexus formation

It was observed that the ventral branches of L_4 to L_6 and S_1 to S_3 spinal nerves formed the LSP, innervating the pelvic limb and the abdominal, inguinal, perineal and perianal regions in the chinchilla (Fig. 1). Five nerves originating in the lumbar plexus of the chinchilla had been formed from only 1 ventral spinal branch. The ventral branch of L_1 and L_2 formed the cranial and the caudal iliohypogastric nerves, respectively (Fig. 1). One branch from L_3 gave rise to the ilioinguinal nerve and other branch of this spinal root formed the genitofemoral nerve (Fig. 1). One branch from L_4 gave rise to the lateral cutaneous femoral nerve (Fig. 1). After joining the branch from L_4, L_5 divided into medial and lateral branches. The medial branch formed the femoral nerve, while the lateral branch formed the obturator nerve (Fig. 1). A common root was formed

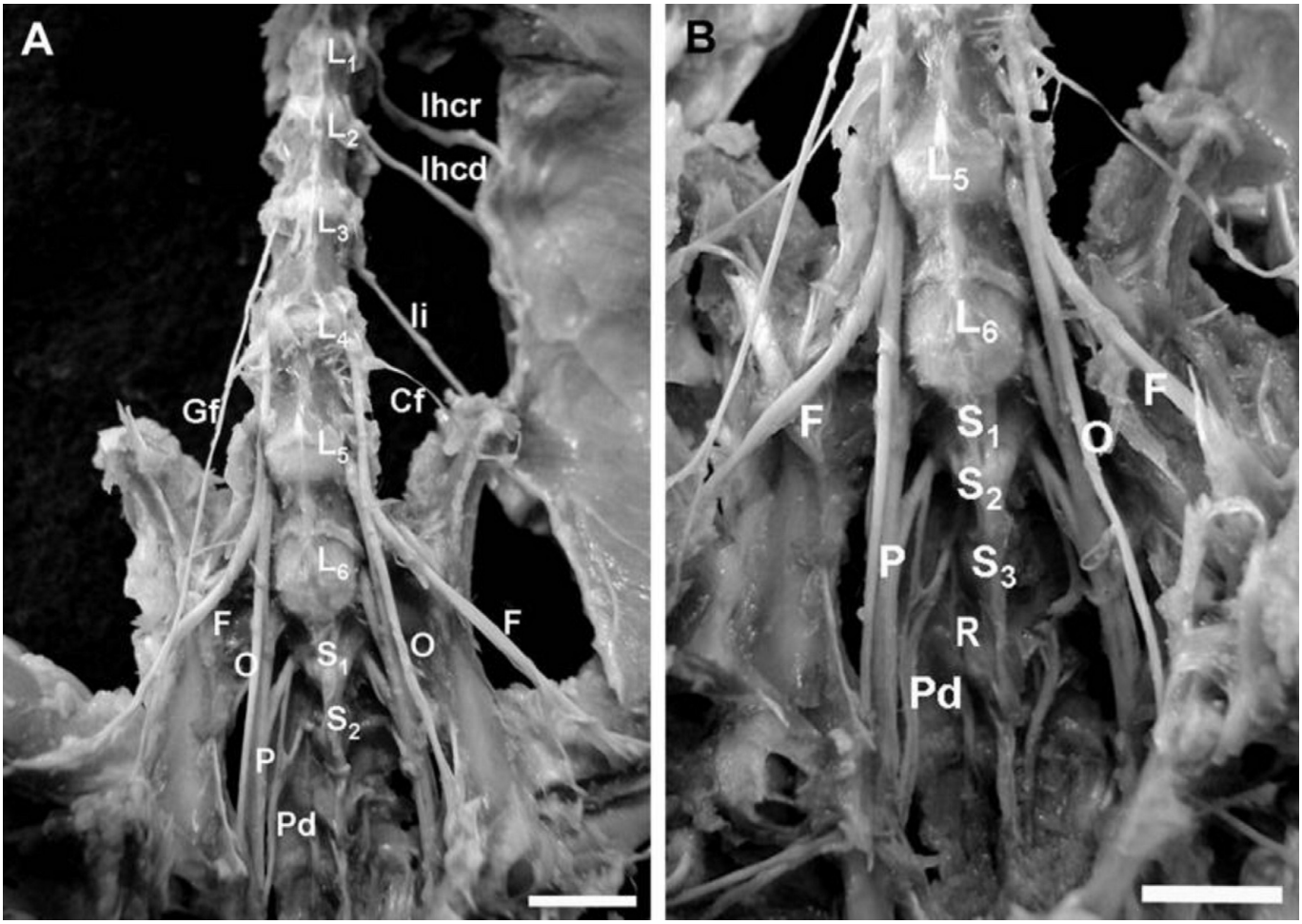

Fig. 1: **Ventral view of the vertebral column showing the spinal origins of the lumbosacral plexus in the chinchilla.** A, **In this view the following unisegmental nerves are visible: cranial iliohypogastric** (Ihcr) **from L_1, caudal iliohypogastric** (Ihcd) **from L_2, ilioinguinal** (Ii) **and genitofemoral** (Gf) **from L_3, lateral cutaneous femoral** (Cf) **from L_4, and the following plurisegmental nerves: obturator** (O) **and femoral** (F) **originating from the union of L_4 and L_5, and pudendal** (Pd) **originating from the joint union of S_{1-2}. The emergence of the ischiadic plexus** (P) **from L_{5-6} and S_1 is also evident.** B, **An enlargement of the ventral view of the vertebral column showing the spinal nerve origins of the following: obturator** (O)**, femoral** (F)**, pudendal** (Pd)**, rectal caudal** (R) **originating from the S_{2-3} and the emergence of the ischiadicus plexus** (P)**.** Scale bar: A: 1 cm; B: 1.5 cm**.**

distally from a branch from L_5, the entire L_6 and a branch from S_1 (Fig. 1). This root gave rise to the ischiadic plexus (cranial and caudal gluteal nerves, caudal cutaneous femoral nerve and ischiadic nerve), branches of which were scattered throughout the posterior limb (Fig. 2). After giving off the 1st branch to form the ischiadic plexus, S_1 merged with S_2 to form the pudendal nerve (Fig. 1), while the other branch of S_2 joined S_3 to form the rectal caudal nerve (Fig. 1). However, in 3 animals, S_3 did not participate in the composition of this root.

Lumbosacral plexus nerve distribution

The cranial iliohypogastric nerve emerged between the *psoas major* and *minor* muscles and divided into 3, forming the medial, intermediate and lateral branches at the medial side of the abdominal wall and peritoneum (Fig. 1). The caudal iliohypogastric nerve supplied the paralumbal fossa, craniolateral part of the femur and the ventral abdominal wall (Fig. 1).

The ilioinguinal and the genitofemoral nerves, after emerging between the lumbar muscles, continued subperitoneally and in a caudo-ventral direction towards the *annulus inguinalis abdominalis* (Fig. 1). These nerves innervated the internal abdominal oblique muscle and the cremaster muscle, the testicular fascia, spermatic funiculus and prepuce in males, the teats in females and the skin of the medial side of the femoral region in both sexes.

The lateral cutaneous femoral nerve (Fig. 1) arose from the LSP, reaching the caudal iliac region by crossing the abdominal muscles. It extended over the external abdominal oblique, iliac and *tensor fasciae latae* muscles, the skin of the femoral region and the craniomedial side of the knee joint.

The femoral nerve originated from the LSP with the obturator nerve (Fig. 1). It was the thickest nerve from the plexus. After emerging between the *psoas major* and *minor* muscles and innervating them, together with the deep lumbar muscles, it reached the femoral space running caudo-ventrally and emitting 2 femoral quadriceps muscle branches. The saphenous nerve arose lower down. It divided into 3 branches to the gracilis, pectineus and sartorius muscles and a branch to supply the skin and fascia in the medial femoral region.

The obturator nerve had a similar origin to the femoral nerve. After leaving the pelvic cavity through the obturator foramen, this supplied branches to the adductor, pectineus, gracilis, internal and external obturator muscles.

The ischiadic plexus was a nerve trunk arising from the union of the spinal nerves L_{5-6} and S_1, which supplied the iliac region dorso-caudally and extended caudally in the femoral region. This plexus branched and gave rise to 4 nerves: cranial gluteal, caudal gluteal, caudal cutaneous femoral and ischiadic (Fig. 2). The cranial gluteal nerve (Fig. 2), after leaving the pelvic cavity through the *incisura ischiadica major*, supplied the branches of the deep gluteus, piriform

and *tensor fasciae latae* muscles. The caudal gluteal nerve (Fig. 2) was a motor nerve arising from the caudal portion of this common trunk and that innervated the superficial gluteus, cranial part of the *biceps femoris, abductor cruris caudalis* and the vertebral head of semitendinous and semimembranous muscles. The medial gluteal muscle was innervated by the 2 gluteal nerves. The caudal cutaneous femoral nerve (Fig. 2) innervated the *biceps femoris* and semitendinous muscles and after passing between these muscles, supplied the skin over the *tuber ischiadicum*, the caudal portion of the femur and by a union with the pudendal nerve, the perineum.

The common trunk continued as the ischiadic nerve after giving rise to the caudal cutaneous femoral nerve (Fig. 2). The ischiadic nerve branched into the proximal muscular branch for the internal obturator, gemelli and *quadratus femori* muscles. This branch extends to the skin after innervating the caudal portion of the *biceps femoris*, semitendinous and semimembranous muscles. Near the knee joint, the ischiadic nerve divided into the caudal cutaneous surae, lateral cutaneous surae, common fibular and tibial nerve. The cutaneous surae lateralis nerve (Fig. 2), first branch of the ischiadic nerve innervated the subcutaneous tissue and skin in the cranial surae region, while the caudal cutaneous surae nerve crossed the caudal sural region and innervated the skin of this region and the common calcaneal tendon (Fig. 2). The tibial nerve (Fig. 2) ran to the level of the tarsal joint, giving off slender branches to the skin in this region, and divided into the dorsal digital and common plantar nerve V. After this branch, the tibial nerve gave off a distal muscular branch that extended to the flexor muscles, ran between the 2 heads of the gastrocnemius and popliteus muscles, continued as branches to the muscles of the plantar surface of the metatarsus and divided into the common plantar digital nerves II, III and IV. The common fibular nerve (Fig. 2) passed over the gastrocnemius muscle and entered the sulcus between the *peroneus longus and extensor digitorium lateralis* muscles, then dividing into the superficial fibular and profound fibular nerves. The superficial fibular nerve innervated the skin of the dorsum of the tarsus and metatarsus and emitted the muscular branches to the cranial tibial, *extensor digitalis longus* and *extensor digitalis lateralis* muscles, and formed the common dorsal digital III and IV nerves. The deep fibular nerve innervated the *fibularis longus* and *fibularis brevis* muscles.

The pudendal nerve (Fig. 1) crossed towards the caudal pelvic aperture where it divided into the dorsal nerves of the penis or clitoris and the superficial and deep perineal nerves. The first innervated the ischiocavernosous, bulbospongiosous and *retractor penis* muscles and the prepuce in male and the *constrictor vulvae* muscle, clitoris and vulva in female. The superficial and deep pudendal nerves innervated the skin and muscles of the anal and perianal regions.

The rectal caudal nerve (Fig. 1) innervated the region up to the end of the rectum, the sphincter muscles of the anus and the skin of the anal region.

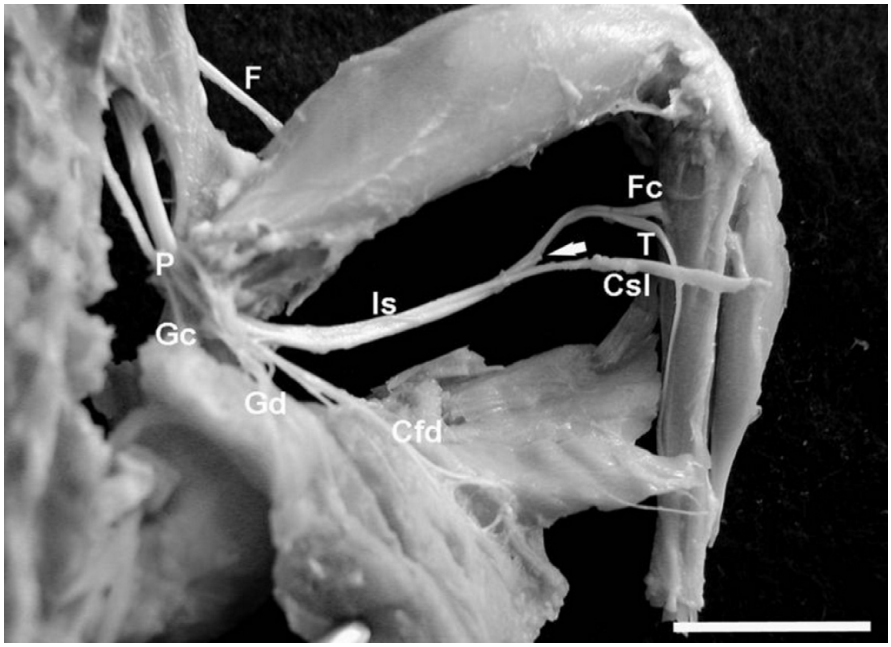

Fig. 2: **Ventro-lateral view of the nerves originating from a common root formed by the union of $L_{5–6}$ and S_1 spinal nerves, and constituting the ischiadic plexus** (P) **in the gluteal region and hind limb of the chinchilla. The following nerves arose from this plexus: cranial gluteal** (Gc)**, caudal gluteal** (Gd)**, caudal cutaneous femoral** (Cfd) **and ischiadic** (Is)**. The ischiadic nerve divided into the lateral cutaneous surae** (arrow, Csl), **common fibular** (FC) **and tibial** (T). Scale bar: 1 cm**.**

DISCUSSION

Lumbosacral plexus formation

It has been reported that the LSP was formed by the union of the ventral branches that vary between the L_2 to L_6 and S_1 to S_4 spinal nerves in domestic mammals[16,19,28,37] and L_3 to L_5 and S_1 spinal nerves in South American fur seal[9]. In species similar to the chinchilla it was observed that LSP was formed by ventral branches that vary between $T_{13–15}$, L_1 to L_7 and $S_{1–3}$ spinal nerves[4,13,22,25,26,29].

In the present study it was found that the LSP was formed by the union of the ventral branches of spinal nerves L_4 to L_6 and S_1 to S_3. In terms of the branches that contributed to formation of the LSP (invariably the last 3 lumbar spinal nerves and the 1st 3 sacral nerves), the LSP in the chinchilla is close to that of the cat[19], guinea pig[13], rabbit[26], Brazilian rock cavy[25] and South American fur seal[9].

However, the number of the spinal nerves was not the same owing to the different number of vertebrae in each species. The LSP formation was totally different from those reported for the rat[22], agouti[29] and porcupine[4].

A common nerve root was found in the LPS that gives rise to the nerves innervating the posterior limbs of the chinchilla, which in the present study is referred to as the ischiadic plexus, according to the nomenclature used by Schwarze and Schröder[36]. We chose this name because this constitutes a common root, originating from different spinal nerves and that forming a common trunk that branches into nerves: the cranial gluteal, caudal gluteal, caudal cutaneous femoral and ischiadic. A common root has been reported in ruminants[19], dogs[19,28], humans[17], cats[19,20] and South American fur seals[9]. However, the term ischiadic plexus was used only in the South American fur seal.

There are many reports giving the data about the formation of this common root in rodents. In the Brazilian rock cavy[25] it was reported that $L_{5–6}$ or $L_{6–7}$ and S_1 contribute to formation of the common root, while in the agouti[29] in some cases $L_{4–5}$ contribute with $L_{6–7}$ and S_1 to the common root. However, in porcupines[4] the common root consisted of the entire L_4 and S_1 and a slender branch from S_2 and L_3. Two descriptions were found for the rat. Asato

et al.[1] reported that L_4 and L_5 always and L_6 rarely contribute to formation of the common root. On the other hand, other authors stated that $L_{4–6}$ and $S_{1–2}$ contribute to formation of the common root in rats[22,35,39]. However, in the LSP of the chinchilla this common root was formed by $L_{5–6}$ and S_1 which was consistent with what has been described in the rabbit[26], agouti[29] and Brazilian rock cavy[25], but not in other rodents[1,4,13,22,35,39] and some mammals, including humans [9,17,19,28,37].

Lumbosacral plexus nerve distribution

The formation of the iliohypogastric and ilioinguinal nerves in various domestic mammals has been described as follows: in species that have 6 lumbar vertebrae (herbivores), the iliohypogastric nerve arises from the ventral branch of L_1 and the ilioinguinal nerve arises from L_2[16,19,37]. Species that have 7 lumbar vertebrae (carnivores) have 2 iliohypogastric nerves, cranial and caudal, which arise from the ventral branches of L_1 and L_2, and the ilioinguinal nerve, which arises from the ventral branch of L_3[16,19,28,37]. However, the chinchilla has 6 lumbar vertebrae, but L_1 and L_2 give rise to the cranial and caudal iliohypogastric nerves and the ilioinguinal nerve arises from L_3. In all the studies it was reported that these 2 nerves innervate the same regions. Therefore, these results were different from those obtained for other rodents[3,4,13,22] and the South American fur seal[9].

The formation of the genitofemoral and lateral cutaneous femoral nerves in the chinchilla was similar to that of sheep, goats[19] and South American fur seals[9] in terms of common origin, while it was completely different from all other animals in its origin from L_3 and L_4[3,4,13,19,26,28]. However, a common origin of the genitofemoral nerve formed by part of L_3 and L_4 joining the common trunk of the obturator and femoral nerves, as described in South American fur seals[9], was not observed.

The formation of the femoral and obturator nerves from the same spinal nerves in the chinchilla was similar to that reported in rats[22], agouti[29], Brazilian rock cavy[25], porcupine[3,4] and other mammals[9,19,28]. However, this study detected that both nerves originated from L_4 and L_5, which differs from previous reports, only being similar to 1 of the types described in the Brazilian rock cavy[25]. The 1st branch arising from the femoral nerve supplied the medial muscles of the femur, while the 2nd branch, the saphenous nerve, innervating the skin and muscles of the posterior limb, extended over the skin of the medial part of the posterior limb in rats[22,39], guinea pigs[13] and rabbits[26].

Although it has already been discussed, an examination of the formation of the ischiadic plexus was necessary to observe the root and the areas of innervation of the cranial gluteal, caudal gluteal, caudal cutaneous femoral and ischiadic nerves individually. Since the literature records different origins for these nerves, the variations are discussed.

In the Brazilian rock cavy the cranial gluteal and the caudal gluteal nerves were described as branches originating from the ischiadic nerve, without considering the formation or existence of the ischiadic plexus[25,34]. Similar descriptions of both gluteal nerves were given for the cat and the dog, where these were considered to be branches of the final portion of the LSP or branches of the ischiadic nerve[19,28]. In some rodents the gluteal nerves originated individually from the spinal nerves that constitute the LSP[3,4,13,22], but in rats the caudal gluteal nerve is a branch of the perineal nerve[22].

The caudal cutaneous femoral nerve in guinea pigs was reported to originate from the LSP with the ischiadic nerve and then to separate from it; in porcupines this nerve arises from the common root with the cranial gluteal, caudal gluteal and ischiadic nerves[3,4] and the presence of this nerve was not mentioned in the Brazilian rock cavy [25,34] or agouti[29].

Like the variation of the lumbar and sacral vertebrae, the nerve roots that form the ischiadic nerve, proved to be distinct for different species but it could be noted that they represent the last spinal nerves forming the LSP[1,3,4,13,19,20,22,25,26,28,29,34,35,38]. The ischiadic nerve, after giving off the caudal cutaneous surae nerve divided equally into the common fibular and tibial nerves as observed in rodents[1,3,13,22,25,29,34,35], rabbits[26] and other mammals [9,16,19,20,28,37,38].

Despite varying information about the origins of these nerves, the innervation areas of the chinchilla were similar to those of rodents[1,3,13,22,25,29,34,35], rabbits[26] and other mammals cited[16,19,20,28,37,38]. However, the results presented in this study show that the cranial gluteal, caudal gluteal, caudal cutaneous femoral and ischiadic nerves arise from a common trunk, the ischiadic plexus, which branches out to innervate the posterior limb, consistent with observations from South American fur seals[9].

In this study, the pudendal nerve arose from $S_{1–2}$ and the rectal caudal nerve originated from $S_{2–3}$. These results differ from all previous descriptions of the origin of these nerves in guinea pigs[13] and rabbits[26]. Neither the formation of the pudendal plexus[22] nor the presence of a common trunk formed by L_5–S_1 as described in rats[27,32] was observed in chinchillas. The common emergence of both nerves was similar only to that described in cats[19,20], dogs[19,28], South American fur seals[9] and, probably in Brazilian rock cavy[25] and porcupines[3,4]. In the chinchilla the pudendal nerve was divided into a superficial and deep perineal nerve as in dogs[19,28].

In conclusion, the formation of the LSP in the chinchilla was partly consistent with the plexus in the guinea pig and Brazilian rock cavy, rabbits and South American fur seals, and differs from all other species discussed. The formation of the common root of the nerves that innervate the posterior limb bore a slight similarity to rabbits, agouti and Brazilian rock cavy, while it was significantly different from the remaining rodents and other mammals discussed. The authors of this study also evaluated the formation of the nerves originating from the LSP in the chinchilla and came to the following conclusions: the iliohypogastric nerve was present and consisted of cranial and caudal nerves; the ischiadic plexus was present and formed a common root that innervated the posterior limb and gave rise to the cranial and caudal gluteal, caudal cutaneous femoral and ischiadic nerves; the ischiadic nerve divided into the lateral cutaneous surae, caudal cutaneous surae, common fibular and tibial nerves; the pudendal nerve divided into 3 nerves, namely the dorsal penis (male) or clitoris (female), superficial and deep perineal nerves. Knowing the distribution of the ischiadic nerve in chinchilla enables delimitation of a safe area for intramuscular application of drugs, namely the semimembranous muscle region or even the caudal face of the semitendinous muscle. The data presented are similar to those reported previously in rodents and other mammals, but some characteristics were shown to be peculiar to the chinchilla.

REFERENCES

1. Asato F, Butler M, Blomberg H, Gordh T 2000 Variation in rat sciatic nerve anatomy: implications for a rat model of neuropathic pain. *Journal of the Peripheral Nervous System* 5: 19–21
2. Bishop I R 1993 Other cavy-like rodents. In MacDonald D (ed.) *The encyclopedia of mammals.* Harper Collins, London: 700–703
3. Aydin A 2009 The dissemination of the pelvic limb nerves originating from the lumbosacral plexus in the porcupine (*Hystrix cristata*). *Veterinární Medicina* 54: 333–339
4. Aydin A, Dinc G, Ylmaz S 2009 The spinal nerves that constitute the plexus lumbosacrales of porcupines (*Hystrix cristata*). *Veterinární Medicina* 54: 194–197
5. Barone R, Pavaux C, Blin P C, Cuq P 1973 *Atlas of rabbit anatomy.* Masson et Cie, Paris
6. Carleton M D, Musser G G 2005 Order Rodentia. In Wilson D E, Reeder D M (eds) *Mammal species of the world: a taxonomic and geographic reference.* Johns Hopkins University Press, Baltimore: 745–752
7. Castro T F, Pereira P C G, Pereira M A M,

Bombonato P P, Rickes E M 2007 Formation of the portal venous system in *Chinchilla lanigera. Brazilian Journal of Veterinary Research and Animal Science* 44: 44–48
8. Castro T F, Dummer R J, Rickes E M, Pereira M A M 2010 Morphological, morphometric and topographical description of the digestive tract in *Chinchilla lanigera. Brazilian Journal of Veterinary Research and Animal Science* 47: 86–94
9. Castro T F, Souza D A S, Silva Filho R P, Pereira M A M 2009 The lumbar and sacral innervation of the *Arctocephalus australis*: sistematization and distribution. *Brazilian Journal of Veterinary Research and Animal Science* 46: 404–411
10. Cevik-Demirkan A, Ozdemir V, Demirkan I, Türkmenoglu I. 2007. Gross morphological features of plexus brachialis in the chinchilla (*Chinchilla lanigera*). *Journal of the South African Veterinary Association* 78: 21–24
11. Chiasson R B 1980 *Laboratory anatomy of the white rat.* Brown Company Publisher, Iowa
12. Cook M J 1965 *The anatomy of the laboratory mouse.* Academic Press, London, New York
13. Cooper G, Schiller A L 1975 *Anatomy of the guinea pig.* Harvard, University Press, Cambridge, Massachusetts
14. Crouch J E 1985 *Text-atlas of cat anatomy.* Lea & Febiger, Philadelphia
15. De Araujo A C, Campos R 2009 Systematization, distribution and territory of the middle cerebral artery on the brain surface in chinchilla (*Chinchilla lanigera*). *Anatomia Histologia Embryologia* 38: 12–17
16. Dursun N 2000 *Veterinary anatomy III.* Medisan Yayinevi, Ankara
17. Ebraheim N A, Lu J, Yang H, Huntoom M, Yeasting R A 1997 Lumbosacral plexus: a histological study. *Acta Anatomica* (*Basel*) 158: 274–278
18. Gamba C O, Castro T F, Rickes E M, Pereira M A M 2007 The nervous territories of the brachial plexus in *Chinchila lanigera. Brazilian Journal of Veterinary Research and Animal Science* 44: 283–289
19 Getty R 1975 *Sisson and Grossman's The anatomy of the domestic animals* (5th edn). W B Saunders Company, Philadelphia
20. Ghoshal N G 1972 The lumbosacral plexus (plexus lumbosacrales) of the cat (*Felis domestica*). *Anatomischer Anzeiger* 131: 272–279
21. Greenaway J B, Partlow G D, Gonsholt N L, Fisher K R 2001 Anatomy of the lumbosacral spinal cord in rabbits. *Journal of the American Animal Hospital Association* 37: 27–34
22. Greene E C 1968 *Anatomy of the rat.* Hafner Publishing Company, New York and London
23. Jiménez J E 1994 Overuse and endangerment of wildlife: the case of chilean mammals. *Medio ambiente* (*Chile*) 12: 102–110
24. Jiménez J E 1996 The extirpation and current status of wild chinchillas *Chinchilla lanigera* and *C. brevicaudata. Biological Conservation* 77: 1–6
25. Lacerda P M O, Moura C E B, Miglino M A, Oliveira M F, Albuquerque J F G 2006 Origin of lumbar sacral plexus of rock cavy (*Kerodon rupestris*). *Brazilian Journal of Veterinary Research and Animal Science* 43: 620–628
26. Mclaughlin C A, Chiasson R B 1987 *Laboratory anatomy of the rabbit.* W C Brown Company, Dubuque, Iowa
27. Mckenna K E, Nadelhaft I 1986 The organization of the pudendal nerve in the male and female rat. *Journal of Comparative Neurology* 248: 532–549
28. Miller M, Christensen G, Evans H 1964 *Anatomy of the dog.* W B Saunders Company, Philadelphia
29. Nunes L C, Silvino M J 1996 Formação do plexo lombossacral em cutia dourada (*Dasyprocta aguti*). In *Anais* XVII *Congresso Brasileiro de Anatomia, 17*. Sociedade Brasileira de Anatomia, Fortaleza, Brazil: 139
30. Ozdemir V, Cevik-Demirkan A, Türkmenoglu I 2008 The right coronary artery is absent in the chinchilla (*Chinchilla lanigera*). *Anatomia, Histologia and Embryologia* 37: 114–117
31. Ozdemir V, Cevik-Demirkan A, Türkmenoglu I 2008 Subgross and macroscopic investigation of blood vessels originating from aortic arch in the chinchilla (*Chinchilla lanigera*). *Anatomia Histologia Embryologia* 37: 131–133
32. Pacheco P, Camacho M A, García L I, Hernández M E, Carrillo P, Manzo J 1997 Electrophysiological evidence for the nomenclature of the pudendal nerve and sacral plexus in the male rat. *Brain Research* 763: 202–208
33. Rodrigues H 1998 *Técnicas anatômicas* (2nd edn). Arte Visual, Vitória, Brazil
34. Santos R C, Albuquerque J F G, Silva M C V, Moura C E B, Chagas R S N, Barbosa R R, Miglino M A 2006 Ischiatic nerve anatomy in mocós (*Kerodon rupestris* Wied, 1820). *Brazilian Journal of Veterinary Research and Animal Science,* 43: 647–653
35. Schmalbruch H 1986 Fiber composition of the rat sciatic nerve. *Anatomical Record* 215: 71–81
36. Schwarze E, Schröder L 1970 *Compendio de anatomia veterinaria. Tomo IV – Sistema nervioso & órganos de los Sentidos.* Zaragoza
37. Tecirlioglu S 1983 *Comparative anatomy of the nervous system in animals.* Ankara University Press, Ankara
38. Ueyama T 1978 Topography of root fibers within sciatic-nerve trunk of dog. *Journal of Anatomy* 127: 277–290
39. Vejsada R, Hnik P 1980 Radicular innervation of hind-limb muscles of the rat. *Physiologia Bohemoslovaca* 29: 385–392
40. World Association of Veterinary Anatomists 2005 *Nomina anatomica veterinaria* (5th edn). Knoxville, Tennessee