

Diagnostic value of magnetic resonance imaging and computed tomography for oral masses in dogs

U C M Kafka^{a*}, A Carstens^b, G Steenkamp^c and H Symington^d

ABSTRACT

The purpose of this study was to determine the diagnostic value of magnetic resonance imaging (MRI) and computed tomography (CT) in oral masses of dogs. Nineteen dogs underwent clinical, MR and CT examinations. Eleven malignant and ten non-malignant masses were evaluated. Osteosarcoma was the most commonly found malignant oral mass and gingival hyperplasia was the most commonly found benign mass. The results showed that MRI provided more accurate information regarding the size of the masses and invasion of adjacent structures although MRI and CT show similar accuracy in assessment of bone invasion. Calcification and cortical bone erosion was better seen on CT images. Whereas contrast-MRI provided useful additional information, contrast-CT had no added benefit. In general, oral masses located in the caudal mandible, oropharynx and maxilla are better evaluated using MRI, once the histological type has been verified.

Key words: computed tomography (CT), dogs, magnetic resonance imaging (MRI), oral masses.

Kafka U C M, Carstens A, Steenkamp G, Symington H **Diagnostic value of magnetic resonance imaging and computed tomography for oral masses in dogs.** *Journal of the South African Veterinary Association* (2004) 75(4): 163–168 (En.). P.O. Box 92404, Mooikloof, 0059 South Africa.

INTRODUCTION

Oral tumours are the 4th most common neoplasm in the dog, representing approximately 5–7 % of all tumours^{5,7,22,24}. The incidence of oral tumours is known to vary among breeds. Squamous cell carcinoma (SCC) and fibrosarcoma (FS) tend to occur in large breeds, whereas malignant melanoma occurs more commonly in heavily pigmented small breeds²². The most common sites for neoplasia within the oropharynx in order of decreasing frequency are the gingival and dental alveoli, the tonsils, the lips and the buccal mucosa, the palate and the tongue²². The term 'epulis' refers to any tumour or tumour-like lesion on the gingiva^{20,21}. Epulis is not a diagnosis in itself and its true nature must be determined histologically. A number of hisopathological entities can clinically present as an 'epulis', including all the malignant tumour types²⁰.

Survey radiographs of oral masses in

dogs give limited information in that at least 40 % of the bone has to be eroded before radiographic changes are seen²⁴. In addition, soft tissue swelling and margins cannot be clearly defined. Computed tomography (CT) has been generally used by the Dentistry Section of the Onderstepoort Veterinary Academic Hospital as an advanced imaging modality to further evaluate oral masses (90 % of which are tumours) in dogs. The soft-tissue margins of these masses were indistinct on CT images. Human literature^{1,4,9,10–12,15,16,18,19,25} suggests that magnetic resonance imaging (MRI) may be superior in assessing the extent and invasion of oral masses, in particular, oral tumours. The purpose of this study was to ascertain which of the 2 advanced imaging modalities, CT or MRI, would provide the most accurate information regarding margins and possible invasion of oral masses in dogs. This information is vital for the longterm prognosis, radiation and/or surgical planning and subsequent removal of oral masses.

MATERIALS AND METHODS

Nineteen dogs with oral masses were included in this study. The preliminary work-up consisted of a full clinical evaluation, macroscopic assessment of oral masses (describing size, shape and

margination), palpation of regional and peripheral lymph nodes, left and right lateral recumbent thoracic radiographs³ as a preliminary screening method for thoracic metastases, and blood urea nitrogen strip testing. The patients were then taken to a private human hospital for the MRI and CT examinations. General anaesthetic was given according to a previously described protocol⁸. Patients underwent MR examinations before the CT scans because MR artefacts were anticipated from the use of iodinated CT contrast media. The MR scanner was a 1.5Tesla Visart Toshiba unit. A head coil was used for the large dogs, an extremity coil for the smaller dogs. T₂-weighted and pre- and post-contrast T₁-weighted sequences were most commonly used and sequences were performed in sagittal, dorsal and transverse planes. The selected slice thickness was determined by the size of the mass in the particular patient, but the minimum slice thickness was 3 mm. For the post-contrast MR examinations, a gadolinium compound (Magnevist, Schering Plough), was injected intravenously by hand in a bolus at a dose of 1 ml/5 kg and the post-contrast T₁-weighted sequence was acquired immediately. The entire MR-procedure lasted approximately 40–50 minutes.

Soft tissue and bone windows were obtained for the CT studies utilizing a helical 3rd generation Express-SX Toshiba CT unit. For the contrast studies, a non-ionic, water-soluble contrast medium, iohexol (Omnipaque 300, Nycomed) was injected intravenously by hand in a bolus at a dose rate of 2 ml/kg. Post-contrast images of the oral masses and of the thorax were obtained immediately following contrast injection. Soft tissue and bone windows were obtained. The entire CT procedure lasted approximately 10 minutes. Size, shape, margination, location of the oral masses and invasion of adjacent structures were assessed on pre- and post-contrast MR and CT images. The thorax was evaluated on CT images to exclude pulmonary metastases. All masses were biopsied and the tissue submitted for histopathological evaluation.

^aP.O.Box 92404, Mooikloof, 0059, South Africa.

^bC/o Department of Companion Animal Clinical Studies, Section of Diagnostic Imaging, Private Bag X04, Onderstepoort, 0110, South Africa.

^cDepartment of Companion Animal Clinical Studies, Section of Dentistry, Private Bag X04, Onderstepoort, 0110 South Africa.

^dWeir and Partners, Pretoria East Hospital, South Africa.

*Author for correspondence.

E-mail: alancham@mweb.co.za

Received: March 2004. Accepted: July 2004.

Table 1: Summary of findings of clinical cases.

Signalment	Location	Histopathology	WHO stage	Surgery
1. Pitbull cross, 7 yr male	R rostral to mid mandible	Osteosarcoma	II	Yes, with follow-up chemotherapy
2. Bull mastiff cross, 8 yr female	First removed, 'aggressive' epulis diagnosed, then entire cranium originating from L maxilla at the level of PM4	Osteosarcoma	III	No
3. Spaniel, 14 yr female	L caudal mandible at level PM4	Mast cell tumour	III	Yes, with chemotherapy
4. Maltese, 12 yr female	R maxilla between PM 1+2	Osteosarcoma	II	Yes
5. Boxer cross, 6 yr male	Multifocal on mandible and maxilla	Benign gingival hyperplasia and POF	I	Yes
6. Ridgeback, 8 yr female	Rostral incisive bone on R between upper I 1+2	POF	I	Yes
7. Irish wolfhound, 4 yr male	Beneath the tongue in the muscle	Abscess	I	Yes
8. Sheltie 10 yr female	R maxillary behind right upper canine	Focal fibrous hyperplasia	I	Yes
9. Border collie 7 yr male	Rostral L mandible	Focal fibrous hyperplasia initially, 1 yr later leiomyosarcoma	I	Yes, 1 yr later
10. Border collie, 6 yr female	Rostral L mandible	Focal fibrous hyperplasia and secondary pyogenic granuloma	I	Yes
11. Airedale terrier, 8 yr male	R maxilla, canine and up to PM3	SCC	II	No
12. Large cross-breed, 9 yr female	R maxilla, caudal to canine tooth	SCC	II	No
13. Bull mastiff, 5 yr male	Left rostral maxilla	Focal fibrous hyperplasia with plasmacytic infiltration	I	Yes
14. Bull mastiff, 10 yr female	Left caudal mandible	Osteosarcoma	III	Yes, suspected metastasis to pelvis 3 months later
15. Staffie × corgi, 13 yr male	L maxilla, extending towards hard palate and eye	Fibrosarcoma	II	No. Radiation ×3, no response
16. Labrador, 6 yr male	R rostral maxilla, adjacent to canine	Peripheral ameloblastoma	II	Yes
17. Rottweiler, 8 yr female	R maxilla, maxillary recess	Osteosarcoma	II	No
18. Boxer, 18 months male	Pharynx	Pharyngeal mucocoele	I	Yes
19. Rottweiler, 8 yr female	R caudal mandible	Osteosarcoma	II	Yes

PM = premolar, L = left, R = right, yr = year/s, POF = peripheral odontogenic fibroma.

RESULTS

A summary of the findings of all the clinical cases is provided in Table 1. The female to male ratio was 10:9. The age varied from 1.5 to 13 years with a mean age of 8 years. The large breeds outnumbered the small breeds by 16 to 3. Eleven malignant and 10 non-malignant masses were diagnosed histopathologically. One patient (case no. 5) had 2 different histopathological types (focal fibrous hyperplasia and peripheral odontogenic fibroma) and another (case no. 9) was initially diagnosed with focal fibrous hyperplasia which transformed into a leiomyosarcoma within 2 months. The most commonly occurring malignant tumour in this study was the osteosarcoma (5 cases) and the most common non-malignant mass was focal fibrous hyperplasia (5 cases). Five of the patients had malignant tumours that were so extensive and invasive that they were inoperable, but surgery was performed in 14 cases. Table 2 shows the comparison between macroscopically-assessed size, shape and margination of the oral masses, and those on MR and CT examinations. MRI provided more accurate information regarding the size of the

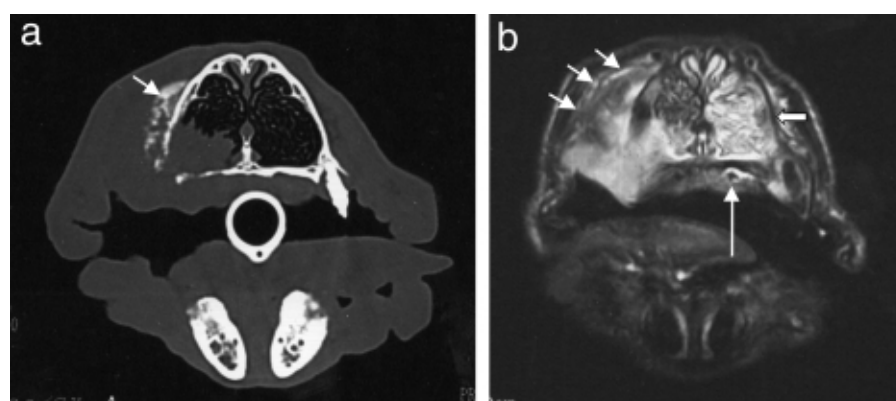


Fig. 1: a: **A computed tomographic bone window image of patient 11. Although bone destruction and extension of the tumour into the R nasal passages is clearly seen, the soft tissue margins on the buccal aspect are not well defined. Note the intra-lesional calcification (arrow) not seen on MR image (1b). Diagnosis: squamous cell carcinoma.**

b: **T₂-weighted MR image of patient 11. Similar bone destruction and extension into the nasal cavity is seen but soft tissue margins are now clearly defined on the buccal aspect (short arrows). A 2nd tumour focus (long arrow) as well as hypostatic oedema (block arrow) of the opposite nasal passage could not be seen on CT images.**

masses and invasion of adjacent structures, especially that of soft tissue (Fig. 1). Extension of the tumour within bone was also better seen on MR images (Fig. 2). Visualisation of the masses in 3 different planes on MR images facilitated tumour definition and delineation. Transverse-only CT images were reconstructed on 2

patients in an attempt to obtain a similar 3-dimensional view of the mass. The small size and sample volume of the respective masses resulted in poor 3D reconstruction in these cases.

An advantage CT had over MRI was that slice thickness could be reduced to 1 mm if tumours were very small, that is

Table 2: Comparison of macroscopic assessment, CT and MRI with regards to size and margination of oral masses in dogs.

	Macroscopic assessment	Computed tomography	Magnetic resonance imaging
CASE NO. 1	30 × 50 mm soft tissue mass of R rostral to mid-mandible, displacing teeth laterally.	36 × 39 × 60 mm expansive bone lesion, bone destruction clearly seen, soft tissue margins and tumour margins within bone poorly-defined. Tooth displacement clearly seen.	37 × 40 × 62 mm bone and soft tissue lesion showing the typical 'popcorn-like' multi-loculated appearance of an osteosarcoma. Tumour margins within bone clearly defined. Tooth displacement clearly identified. Heterogenous contrast uptake, clearly defining margins especially within bone.
CASE NO. 2	Moderate swelling of the L frontal sinus region, mild 2 × 3 cm hard swelling in the region of previous surgical site.	Entire cranium shows marked bone destruction with amorphous new formation evident in adjacent soft tissue.	Entire cranium shows typical multi-loculated appearance of an osteosarcoma but tumour margins at previous surgical site are poorly defined. Uniform contrast uptake.
CASE NO. 3	An ulcerative, reddish, 13 × 23 mm sunken soft tissue mass was seen surrounding PM4 of the L caudal mandible.	Poorly-defined soft tissue mass seen but unable to accurately assess margins. No bone involvement noted.	Well-defined 20 × 24 × 18 mm soft tissue mass, no bone involvement, surrounds tooth mesially, buccally and dorsally but only extends 1/3rd of the tooth root distally. Homogenous contrast uptake.
CASE NO. 4	Small 5 × 8 mm soft tissue mass between PM1 and 2 of R maxilla.	9 × 8 mm bone and soft tissue lesion, altered and thickened cortical bone evident buccally.	11 × 8 mm soft tissue mass seen only on T1-weighted images, T2 definition poor. Bone involvement not clearly seen. Ring enhancement seen.
CASE NO. 5	Multifocal, raised soft tissue lesions of varying sizes up to 3 × 8 mm along the gingival of maxillae and mandibles.	Poorly-defined soft tissue masses, no sign of bone erosion, occasional metaplastic bone evident.	Multifocal soft tissue lesions, several of which surround teeth, no evidence of bone destruction but metaplastic bone not seen. Homogenous contrast uptake.
CASE NO. 6	A slightly raised non-pigmented area is seen between R 1st and 2nd incisivae on the rostral maxilla, wedging the teeth apart and mildly displacing them laterally.	Displacement of teeth clearly evident, soft tissue component too poorly defined to be measured.	Displacement of teeth also seen, soft tissue component 3 × 12 × 8 mm and triangular shaped. Homogenous contrast uptake.
CASE NO. 7	Soft tissue mass could be felt in lingual muscles but could not be seen.	Mass could not be defined.	Poorly defined soft tissue mass of about 25 × 30 × 35 mm with heterogenous contrast uptake.
CASE NO. 8	A 3 × 5 × 10 mm raised, almost pedunculated mass is seen just caudal to R maxillary canine.	Soft tissue mass about 14 × 5 × 8 mm, no evidence of bone destruction. Cannot define proximal soft tissue border.	Soft tissue mass 16 × 9 × 9 mm seen extending lingually up the side of the canine root by at least 3 mm. Homogenous contrast uptake.
CASE NO. 9	A 30 × 20 mm raised soft tissue mass is seen between L canine and PM 1 on the mandible.	Soft tissue mass 30 × 20 × 20 mm, ventral margins poorly visible. No bone involvement.	Soft tissue mass 32 × 22 × 23 mm, ventral margin extends halfway down the canine root. Heterogenous contrast uptake.
CASE NO. 10	A 12 × 15 × 18 mm hard soft tissue mass is seen on the rostral mandible, craniolateral to the L canine.	Soft tissue mass 22 × 20 × 16 mm shows marked metaplastic bone formation, no erosion of adjacent bone seen.	Heterogenous soft tissue mass of 22 × 21 × 21 is seen mildly surrounding the L canine rostrally and lingually. Heterogenous contrast uptake.
CASE NO. 11	A fairly flat, reddish, 25 × 20 mm ulcerated mass is seen surrounding R maxillary canine and PM1-2.	Soft tissue mass 30 × 25 × 26 mm with obvious bone destruction and extension into the R nasal cavity.	34 × 28 × 32 mm soft tissue mass, bone destruction and extension into R nasal cavity clearly evident.
CASE NO. 12	Fairly flat, ulcerative 20 × 20 mm soft tissue mass on the R maxilla caudal to the canine and surrounding PM2. PM 1 absent.	35 × 36 × 38 mm soft tissue mass, dorsal margins poorly defined, metaplastic bone/ periosteal reaction seen on the lateral aspect of maxilla. Extension into nasal cavity evident.	39 × 36 × 41 mm soft tissue mass extending into nasal cavity, bone erosion and destruction evident. Heterogenous contrast uptake seen. Two additional foci of 14 × 23 mm and 17 × 29 mm seen only on dorsal slices.
CASE NO. 13	Small pedunculated 4 × 8 mm mass adjacent to PM1 buccally and just caudal to L maxillary canine.	Poorly defined soft tissue mass of 4 × 10 × 6 mm. No bony changes seen.	Soft tissue mass of 8 × 24 × 18 mm with heterogenous contrast enhancement.
CASE NO. 14	Hard, multilobulated 40 × 60 mm mass with loss of M2 and 3 in the L caudal mandible. Appears to involve bone.	40 × 45 × 48 mm expansive bone mass with amorphous bone formation seen in adjacent soft tissue. Soft tissue margins poorly defined.	45 × 49 × 52 mm bone and soft tissue mass with marked heterogenous contrast uptake. Typical 'popcorn'-like appearance on T2-weighted images. Tumour margins within bone well defined, especially on post-contrast images.
CASE NO. 15	55 × 45 × 50 mm solid soft tissue mass on the lateral aspect of the L maxilla, apparently extending towards the L eye.	45 × 30 × 60 mm soft tissue mass with intra-lesional mineralisation and destruction of the L maxilla with invasion into the L nasal cavity.	45 × 46 × 69 mm soft tissue mass with clear bone destruction and invasion of the L nasal cavity. Homogenous contrast uptake enhanced caudal margination of mass.
CASE NO. 16	10 × 20 × 20 hard mass on the R rostral maxilla, lateral to canine.	Fairly expansile 25 × 12 × 22 mm bone mass with cortical destruction evident laterally.	28 × 12 × 25 mm bone and soft tissue mass with heterogenous contrast uptake.
CASE NO. 17	Hard 75 × 30 mm mass on the R maxilla and maxillary recess resulting in moderate exophthalmus. Mildly ulcerated intra-orally.	80 × 52 × 58 mm destructive bone and soft tissue mass, dorsal displacement of L eye clearly visible, amorphous bone evident on remnant zygomatic arch. Invasion into nasal cavity evident.	87 × 62 × 59 bone and soft tissue mass with marked heterogenous contrast uptake evident. Extension into nasal cavity and orbit with resultant dorsal displacement of L eye clearly visible. Typical 'popcorn'-like appearance on T2-weighted images.
CASE NO. 18	A fairly solid bulging soft tissue mass is suspected in the L retro-pharyngeal region, not clearly seen through the soft palate.	A poorly-defined slightly hypodense 30 × 30 × 30 mm soft tissue mass is seen in the retropharyngeal region just ventral to the L TM joint. Fairly extensive up to 2 mm dystrophic mineralization is seen on the caudolateral and ventral aspects.	A 32 × 30 × 30 encapsulated, fluid-filled mass is seen in the L medial pterygoid muscle. Poorly-defined hypointense mineralization is seen on the caudolateral and ventral aspects. Obvious ring enhancement clearly defines the capsule.
CASE NO. 19	15 × 20 mm hard ulcerative and sunken mass is seen on the buccal aspect of the R caudal mandible. Seems to involve bone, PM4, M1 and 2 absent.	Expansile bone mass of 30 × 35 × 39 mm with poorly defined soft tissue margins. Cortical bone destruction visible dorsally on the lingual aspect of the mandible.	32 × 35 × 42 mm bone and soft tissue mass, heterogenous contrast uptake clearly defines the tumour borders within the bone, loss of teeth evident. Typical 'popcorn'-like appearance on T2-weighted images.

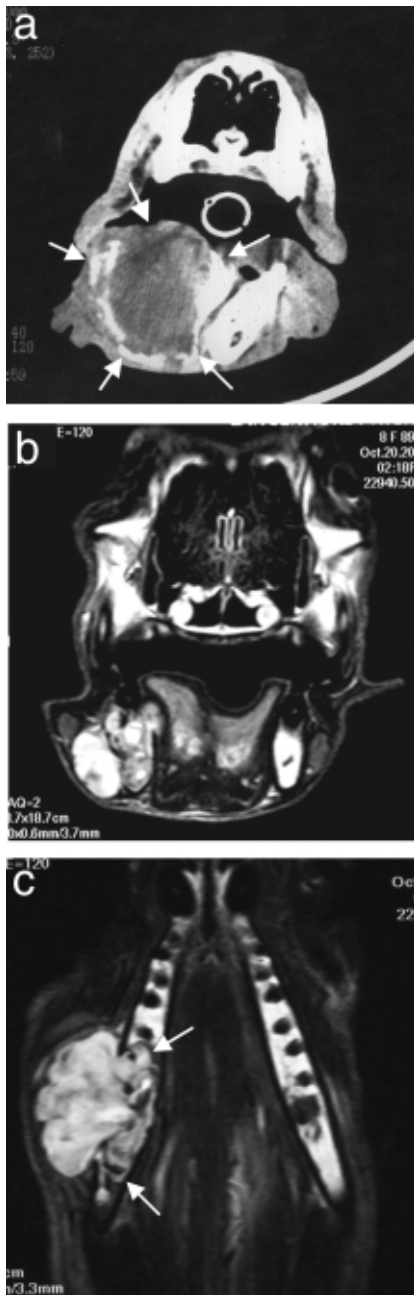

Fig. 2: a: Computed tomographic soft tissue window image of patient 19. An expansile mass can be seen in the region of the caudal right mandible (arrows). Soft tissue margins are indistinct. Diagnosis: osteosarcoma.

b: Patient 19. T₂-weighted MR image of the same tumour slightly more caudally shows distinct soft tissue and bone margins. Compare with (c).

c: T₂-weighted image of the same tumour in the dorsal plane. Note how distinctive the margins of the rostral and caudal aspect of the mass are within the bone (arrows).

5 mm or less. MR images obtained using slice thicknesses of less than 3 mm were grainy and of poor quality, even when, to compensate, acquisition time was lengthened.

Oral masses of the caudal mandible and maxilla that extended into the nasopharynx, nasal passages, or even

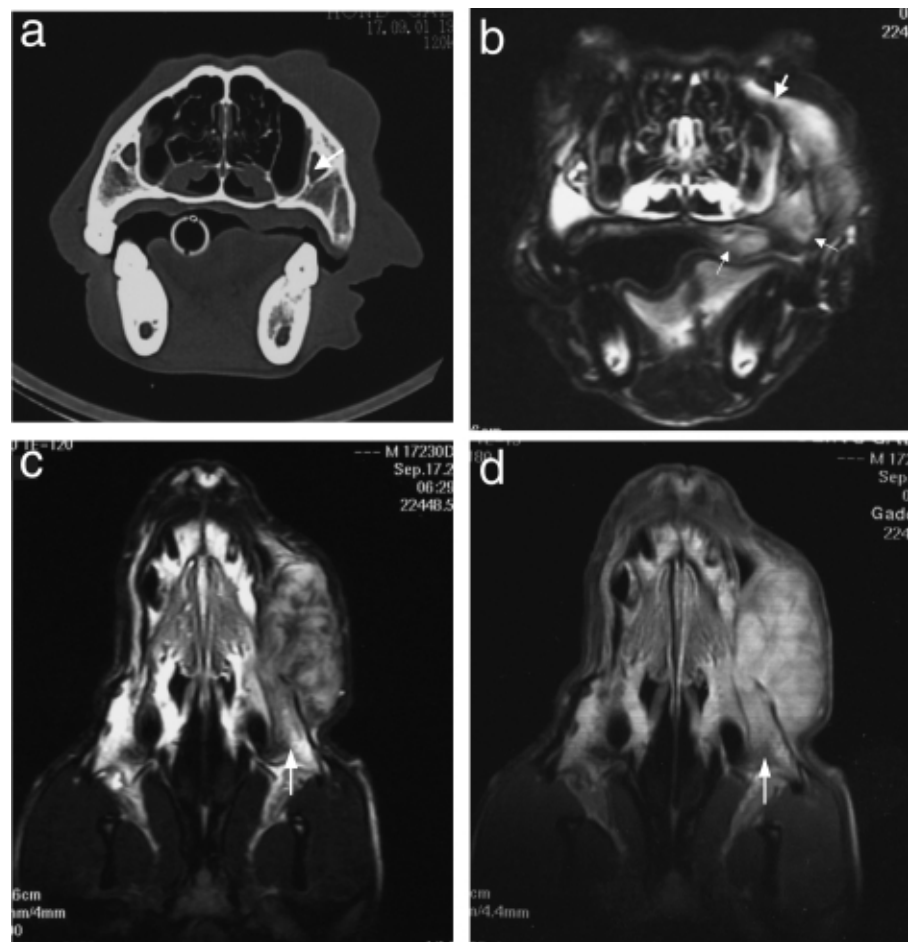


Fig. 3: a: Computed tomographic bone window image of patient 15. An extensive soft tissue mass is evident on the dorsal and lateral aspect of the left maxilla, fairly caudally at the level of the nasopharyngeal opening (1) and the maxillary recess (arrow). Note that the soft tissue margins are poorly defined although grossly visible. Diagnosis: fibrosarcoma.

b: Patient 15. T₂-weighted image of the same tumour. The soft tissue margins are well defined and can be seen extending dorsally to the nasal bone and axially towards the midline of the hard palate (arrows).

c: Patient 15. T₁-weighted pre-contrast image in dorsal plane. Note that the caudal margin of the mass is poorly defined (arrow). Note, too, that the appearance of this tumour type differs greatly from the osteosarcoma (Figs 2, 4, 7); it is more hypointense, a feature of fibrous tissue on T₁ and T₂-weighted MR images.

d: Patient 15. Compare the post-contrast image of the same slice as in (3c). The caudal margin of the tumour is better defined. Note the homogenous uptake of contrast by this tumour type.

brain, were better evaluated with MRI (Fig. 3a–d). Cortical bone erosion, a feature of infiltrative benign and some malignant oral masses and calcification within the mass were better seen on CT images (Fig. 1a). Peri-lesional oedema (often seen around aggressive lesions in the brain) was not a prominent feature of malignant oral tumours.

A single case of post-treatment osteosarcoma proved difficult to evaluate on MR images (Fig. 4a,b). Margins could not be accurately assessed due to the fact that adjacent granulation tissue and inflammation had the same signal intensity as the tumour. Disrupted bone was the main criterion used to distinguish tumour margins and therefore CT proved to be more helpful than MRI. The typical appearance of an osteosarcoma was of a very mottled, multiloculated type of

mass, with intensely hyperintense, 'pop-corn-like' pockets of fluid accumulation apparent on T₂-weighted images. These pockets of fluid were thought to be due to haemorrhagic cysts that form as a result of the severe and aggressive bone destruction that takes place in this tumour type.

Contrast-MRI provided useful additional information in that margins were better defined and the pattern of enhancement could be used to further classify a lesion. No enhancement of the masses, however, could be detected on post-contrast CT images.

DISCUSSION

It appears that the most important diagnostic tool when evaluating oral masses is establishing the histopathological type. Once this information has been acquired, location of the oral mass is the 2nd most

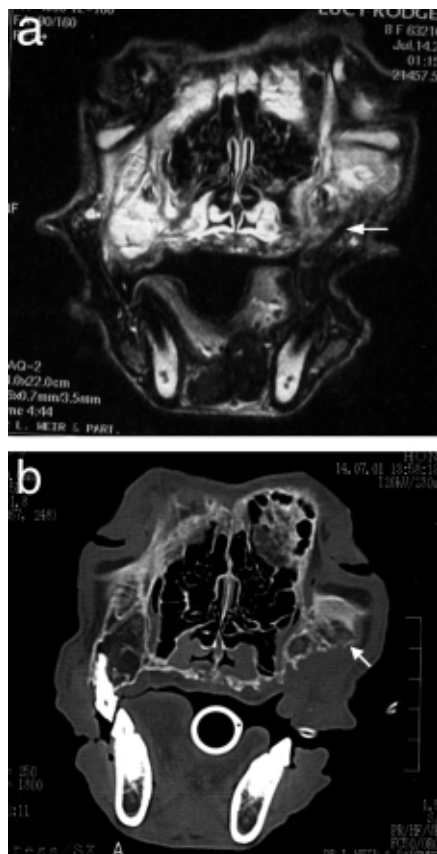


Fig. 4: a. A transverse T₂-weighted MR image of patient 2. The entire hyperintense region is abnormal. Previously performed surgery of the left maxillary region (arrow) made delineation of the tumour from granulation tissue impossible. Diagnosis: osteosarcoma.

b: Patient 2. Computed tomographic image of the same tumour showed that the entire cranium is affected. Extensive bone destruction is evident. The surgical site can clearly be seen (arrow).

relevant criterion. The advent of radical surgical techniques coupled with the use of radiation and/or chemotherapy has dramatically improved survival rate for dogs with oral tumours^{6,13,17,23}. Masses of the rostral mandible do not require further diagnostic imaging techniques as far as surgical planning is concerned. Surgical margins are determined by the histopathological type and radical surgery should be performed on all malignant types. Should inoperable masses require radiation treatment, pre-and post-treatment CT images are advised. Magnetic resonance imaging appears to be too sensitive to inflammation and granulation tissue once treatment or surgery is performed and tumour margins cannot therefore be accurately assessed after treatment. The single case of post-treatment osteosarcoma (Fig. 4a) confirmed the difficulty in differentiating between original mass and granulation tissue on MR images due to the previously performed surgery. In this case, CT provided the necessary clarity (Fig. 4b).

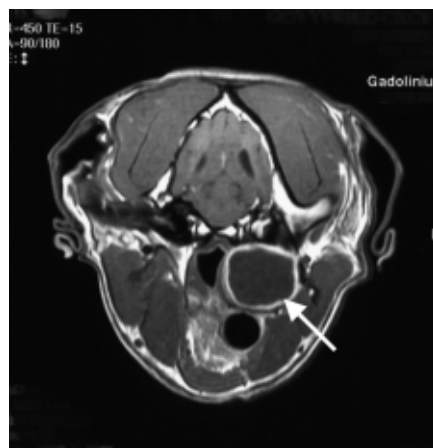

Fig. 5: A post-contrast T₁-weighted image of patient 18. A 'ring'-enhancement pattern (arrow) is seen in those conditions in which any form of capsule is present, as is the case with a pharyngeal mucocoele. This type of enhancement usually indicates a slow-growing, benign process. Diagnosis: pharyngeal mucocoele.

Furthermore, the use of CT has a distinct advantage in anaesthetic risk patients. The entire CT examination is considerably shorter than the MR examination.

All masses were seen with both imaging modalities. However, as expected, the soft tissue margins were only clearly visible on MR images (Fig. 1a,b). Bone invasion could be seen with both imaging modalities, but the margination of the tumour within the bone was better seen on MR images, mainly because of the superior post-contrast studies and the fact that the tumour can be imaged using several primary acquisition planes. (Fig. 2a-c).

The reason why contrast CT was of such poor value was likely to be as a result of hand-administered intravenous injection as opposed to using a pressure-injector. Using the latter would have provided arterial, venous and parenchymatous phases of contrast uptake, but the method is rather costly and it was felt that such a study would go beyond the scope of trying to find the easiest and most effective imaging modality to assess oral masses. A separate study is needed to accurately assess post-contrast CT with pressure-injectors. Technical difficulties and cost may prove to be a major disadvantage compared with the ease of hand-administered intravenous bolus injection of MRI. Contrast MRI generally improved the definition of all the masses (Fig. 4) and the pattern of enhancement can assist in making a diagnosis (Fig. 5). However, contrast uptake in the nasal passages posed a slight problem when the tumour was situated adjacent to nasal turbinates, which normally show moderate enhancement¹⁴. It then became difficult to assess tumour margins accurately on

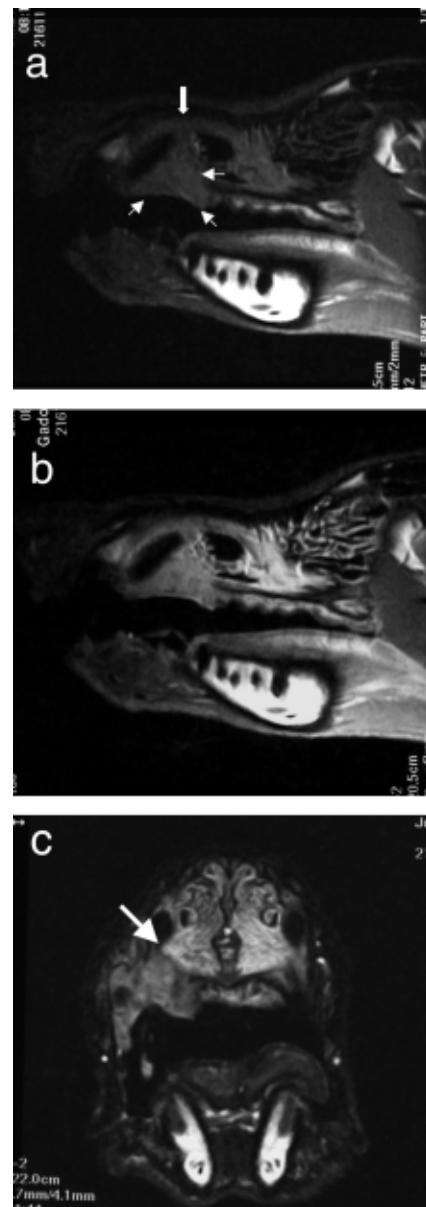


Fig. 6: a: A pre-contrast T₁-weighted image of patient 11 in the sagittal plane. The triangular mass is visible just caudal to the upper canine (small arrows). The dorsal and caudal margins of the mass are indistinct (block arrow). Diagnosis: squamous cell carcinoma.

b: Patient 11. Post-contrast T₁-weighted image of the same slice does not improve dorsal and caudal delineation of the mass. Notice the normal, moderate homogenous contrast uptake by the nasal turbinates.

c: Patient 11. A transverse T₂-weighted image of the same tumour clearly shows that there is no extension of the mass into the nasal turbinates (arrows). The mass is hypointense to the nasal turbinates on T₂-weighted images.

post-contrast T₁-weighted images. In these instances, T₂-weighted images assisted in delineating these tumours (Fig. 6).

The appearance of the osteosarcoma on MR images was characteristic on T₂-weighted images in the 5 cases in this series that these were diagnosed tentatively as such on MR alone (Figs 2, 7).

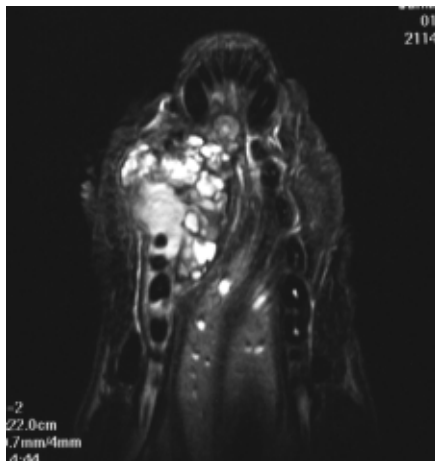


Fig. 7: A dorsal T₂-weighted slice of patient 1. Note the typical multi-lobulated appearance of an osteosarcoma. The markedly hyperintense areas represent haemorrhagic cystic cavities that are an indication of the severe aggressiveness of this tumour type. See also Figs 2, 4. Diagnosis: osteosarcoma.

CONCLUSION

In general, oral masses are better evaluated using MRI, once the histological type has been verified and if the mass is located in the caudal mandible, oropharynx and maxilla. Contrast administration is advised when using MRI. Owing to the short imaging time and the fact that general anaesthesia is not necessarily required, CT may be used in anaesthetic risk patients. When the tumour is of a very small size, CT may also be advantageous in producing thinner slice images.

ACKNOWLEDGEMENTS

We thank all private practitioners for referring these interesting cases to us. Nycomed and Schering-Plough generously donated the contrast media. The staff at Weir and Partners at the Pretoria East Hospital had to endure many hours of our company, and that after normal working hours. To the staff of the Department of Diagnostic Imaging at the Faculty of Veterinary Science, Onderstepoort, in particular Prof. Kirberger and the radiographers on duty, for supporting this project. Finally, we would like to thank

the South African Veterinary Foundation for their assistance in funding this project.

REFERENCES

1. Ariyoshi Y, Simhara M 2000 Magnetic resonance imaging of maxillary cancer – possibility of detecting bone destruction. *Journal of Oral Oncology* 36: 499–507
2. Assheuer J Sager M 1997 *MRI and CT atlas of the dog* (1st edn). Blackwell Science, Berlin.
3. Barthez P Y, Hornof W J, Theon A P, Craychee T J, Morgan J P 1994 Receiver operating characteristic curve analysis of the performance of various radiographic protocols when screening dogs for pulmonary metastases. *Journal of the American Veterinary Medical Association* 204: 237–240
4. Castelijns J A, Van den Brekel M W M 1993 Magnetic resonance imaging evaluation of extracranial head and neck tumors. *Magnetic Resonance Quarterly* 9: 113–128
5. Dhaliwal R S, Kitchell B E, Marretta S M 1998 Oral tumours in dogs and cats. Part I. Diagnosis and clinical signs. *The Compendium of Continuing Education: Small Animal Practice* 20: 1011–1021
6. Dhaliwal R S, Kitchell B E, Marretta S M 1998 Oral tumours in dogs and cats. Part II. Prognosis and treatment. *The Compendium of Continuing Education: Small Animal Practice* 20: 1109–1119
7. Frew D G, Dobson J M 1992 Radiological assessment of 50 cases of incisive or maxillary neoplasia in the dog. *Journal of Small Animal Practice* 33: 11–18
8. Glowaski M M, Wetmore L A 1999 Propofol: application in veterinary sedation and anesthesia. *Clinical Techniques in Small Animal Practice* 14: 1–9
9. Ito J 1990 Diagnostic imaging of maxillofacial lesions with CT and MR. *Dentistry in Japan* 27: 109–113
10. Langlais R P, Van Rensburg L J, Guidry J, Moore W S, Miles D A, Nortje C J 2000 Magnetic resonance imaging in dentistry. *Dentistry Clinics of North America* 44: 411–426
11. Lenz M, Greess H, Baum U, Dobritz M, Kersting-Sommerhoff B 2000 Oropharynx, oral cavity, floor of the mouth: CT and MRI. *European Journal of Radiology* 33: 203–215
12. Leslie A, Fyfe E, Guest P, Goddard P, Kabala J E 1999 Staging of squamous cell carcinoma of the oral cavity and oropharynx: a comparison of MRI and CT in T- and N-staging. *Journal of Computer Assisted Tomography* 23: 43–49
13. Morrison W B 1998 Cancers of the head and neck. In Cann, Carol C *Cancer of dogs and cats: medical and surgical management*. Williams and Wilkins, Baltimore: 511–518
14. Nakayama E, Yonetsu K, Yoshiura K, Araki K, Kanda S, Yoshida K 1996 Diagnostic value of magnetic resonance imaging for malignant tumours in the oral and maxillo-facial region. *Journal of Oral Surgery, Oral Medicine, Oral Pathology, Oral Radiology and Endodontics* 82: 691–697
15. Nallet E, Piekarski J D, Bensimon J L, Ameline E, Barry B, Gehanno P 1999 Value of MRI and computerized tomography scanner in oro-buccopharyngeal cancers with bone invasion. *Annals of Otolaryngology and Chirurgery of the Cervicofacial region* 116: 263–269
16. Niederhagen B, Leipner N, Berge S, van Lindern J J, Appel T 2000 Value of computerized tomography and magnetic resonance imaging in diagnosis of malignancies of the mouth and oropharynx. *Mund Kiefer und Gesichtschirurgie* 4: 217–221
17. Ogilvie G K, Moore A 1995 Tumors of the oral cavity. In Ogilvie K, Moore A S *Managing the veterinary cancer patient: a practice manual*. Veterinary Learning Systems 327–348
18. Pellissier S, Duvoisin B, Fontoliet C, Monnier P 1994 Magnetic resonance imaging and x-ray computed tomography in advanced cancer of the oral cavity. A comparative clinical, radiological and morphological study. *Journal of Radiology* 75: 577–583
19. Van den Brekel M W, Runne R W, Smeel L E, Tiwari R M, Snow G B, Castelijns J A 1998 Assessment of tumor invasion into the mandible: the value of different imaging techniques. *European Radiology* 8: 1552–1557
20. Verstraete F J M 1995 Advanced oral surgery in small carnivores. In Crossley D A, Penman S B.S.A.V.A. *manual of small animal dentistry* (2nd edn). British Small Animal Veterinary Association, Gloucestershire: 202–207
21. Verstraete F J M, Ligthelm A J, Weber A 1992 The histological nature of epulides in dogs. *Journal of Comparative Pathology* 106: 169–182
22. White R A S 1991 The alimentary system. In White R A S (ed.) *B.S.A.V.A. manual of small animal oncology*. British Small Animal Veterinary Association, Gloucestershire: 237–263
23. Widmer W R 1998 Alternate imaging for the diagnosis of cancer. In Morrison W B (ed.) *Cancer in dogs and cats: medical and surgical management*. Williams & Wilkins, Baltimore: 187–213
24. Withrow S 2001 Cancer of the gastrointestinal tract. A. Cancer of the oral cavity. In Withrow S J, MacEwan G E (eds) *Small Animal Clinical Oncology* (3rd edn) W B Saunders, Philadelphia: 305–318
25. Yousem D M, Ara A C 1998 Oral cavity and pharynx. *Radiologic Clinics of North America* 36: 967–981