

## First record of *Acanthocheilonema dracunculoides* from domestic dogs in Namibia

E V Schwan<sup>a\*</sup> and F G Schröter<sup>b</sup>

### ABSTRACT

*Acanthocheilonema dracunculoides* was diagnosed in 2 dogs from Windhoek, Namibia, by acid phosphatase staining of microfilariae. This is the 1st record of *A. dracunculoides* in Namibia.

**Key words:** acid phosphatase staining, *Acanthocheilonema dracunculoides*, dog, microfilariae, Namibia.

Schwan E V, Schröter F G **First record of *Acanthocheilonema dracunculoides* from domestic dogs in Namibia.** *Journal of the South African Veterinary Association* (2006) 77(4): 220–221 (En.). Department of Veterinary Tropical Diseases, Faculty of Veterinary Science, University of Pretoria, Private Bag X04, Onderstepoort, 0110 South Africa.

*Acanthocheilonema dracunculoides* Cobbold, 1870 (syn. *Dipetalonema dracunculoides*), is a vector-borne nematode parasite (Filarioidea: Onchocercidae) of the domestic dog and some sylvatic carnivores (*Proteles cristatus*, aardwolf; *Crocuta crocuta*, spotted hyaena; *Vulpes vulpes*, red fox). The parasite occurs in Europe, Asia and Africa<sup>28</sup>. In Africa it is known to be endemic in Morocco<sup>20</sup>, Algeria<sup>24</sup>, Tunisia<sup>4,27</sup>, Mali<sup>14,22</sup>, Niger<sup>21</sup>, Democratic Republic of Congo<sup>9</sup>, Sudan<sup>2</sup>, Somalia<sup>12</sup>, Kenya<sup>15,16</sup>, Tanzania<sup>26</sup> and South Africa<sup>7</sup>, in which country it was first described by Cobbold from an aardwolf. *Acanthocheilonema dracunculoides* follows an indirect life cycle. In those carnivores, which act as final hosts, the predilection site of the male and female adult parasites is mainly the peritoneal cavity<sup>19</sup>. Infection is often discovered accidentally during intra-abdominal surgical procedures. Males are 15–32 mm long and 0.1–0.2 mm wide, whereas females are 30–60 mm long and 0.1–0.3 mm wide<sup>8,10,11,19,23</sup>. The male spicules are unequal and measure 273–414 and 120–165  $\mu\text{m}$  in length respectively<sup>6,10,11,28</sup>. Sexually mature females are viviparous, i.e. they produce L1-stages, known as microfilariae, which eventually appear in the peripheral blood. Microfilariae are unsheathed and measure 185–276  $\mu\text{m}$  (length) by 4.2–6  $\mu\text{m}$  (width)<sup>6,8,10,11,13,19,23,28</sup>. So far, the louse fly *Hippobosca longipennis* and the hard

tick *Rhipicephalus sanguineus* have been identified as intermediate hosts<sup>15,17</sup>. Microfilariae ingested during blood feeding transform into metacyclic (infective) L3-stages and eventually accumulate in the mouthparts of the respective arthropods involved. Final hosts become infected during blood feeding. The migrational pattern and development within the final hosts are unknown. Similarly, the duration of the prepatent and patent periods is unknown. *Acanthocheilonema dracunculoides* is regarded as largely apathogenic. However, there are several reports from Spain, where high prevalence rates of *A. dracunculoides* have been recorded, according to which infected dogs occasionally present with dermal clinical signs and lesions ranging from pruritus, alopecia, erythema to skin ulcers as well as other clinical signs such as ataxia, incoordination, cachexia and pleural effusion<sup>5,19,25</sup>. From a differential diagnostic point of view, *A. dracunculoides* must always be considered in connection with canine filarioses of other aetiologies and in particular cardiovascular dirofilariosis caused by *Dirofilaria immitis*, colloquially known as heartworm. This paper represents the 1st record of *A. dracunculoides* in Namibia. The parasite was encountered in 2 domestic dogs.

An 8-year-old St. Bernard bitch (Dog A) and a crossbred male dog of unknown age (Dog B) of different ownership were presented to the Windhoek Veterinary Clinic in Windhoek, Namibia, with inappetence and poor appetite. Physical examination of Dog A revealed a slightly elevated rectal temperature of 39.6 °C, marked weight loss, inappetence and ascites. Cardiomegaly and hepatomegaly

were diagnosed on radiographic examination. Physical examination of Dog B additionally revealed vomiting, hind leg lameness and a bilateral corneal oedema. Cam's Quick-stained thin blood films prepared from peripheral blood obtained from a pricked ear pinna of both animals revealed the presence of isolated microfilariae as well as a marked leukocytosis and eosinophilia. Additional blood samples were collected from the cephalic vein of both animals into EDTA coated vacuum tubes to conduct further analysis of microfilariae. Of each sample, a 2 ml aliquot was screened for microfilariae by membrane filtration using 3.0  $\mu\text{m}$  Isopore<sup>®</sup> membrane filters (Millipore) stained with Giemsa<sup>3</sup>. Examination of the Giemsa-stained membrane filters showed the presence of unsheathed microfilariae. They varied in width from 4.7  $\mu\text{m}$  to 5.6  $\mu\text{m}$  at the widest part of the anterior end and varied in length from 218 to 243  $\mu\text{m}$ . The microfilariae were eventually identified by acid phosphatase staining as those of *Acanthocheilonema dracunculoides*, showing the typical somatic pattern of enzyme activity at the cephalic vesicle, excretory pore, 'Innenkörper' (inner body) and anal pore<sup>6,18,29</sup> (Fig. 1). The animals were treated with ivermectin (Ivomec Injection, Merial) at 200  $\mu\text{g}/\text{kg}$  once subcutaneously but could not be followed up. Both animals had never left Namibian territory.

*Acanthocheilonema dracunculoides* has never before been reported from the domestic dog or any sylvatic carnivore in Namibia. Although the species is regarded as largely apathogenic in dogs, there is some evidence reported from Spain that suggests that occasionally the parasite may not be as innocuous as generally assumed<sup>5,19,25</sup>. Dermal clinical signs interpreted as a result of *A. dracunculoides* infection improved following treatment with ivermectin at a dose rate of 50  $\mu\text{g}/\text{kg}$  administered subcutaneously or *per os*<sup>25</sup>. Whether the clinical signs or part of them recorded in Dog A and Dog B are a sequel of the filarial infection diagnosed, cannot be answered considering the scarce clinical information available and the fact that the animals were not followed up.

<sup>a</sup>Department of Veterinary Tropical Diseases, Faculty of Veterinary Science, University of Pretoria, Private Bag X04, Onderstepoort, 0110 South Africa.

<sup>b</sup>Formerly Windhoek Veterinary Clinic–Tierklinik, PO Box 5030, Windhoek, Namibia

\*Author for correspondence.  
E-mail: vschwan@op.up.ac.za

Received: October 2005. Accepted: October 2006.

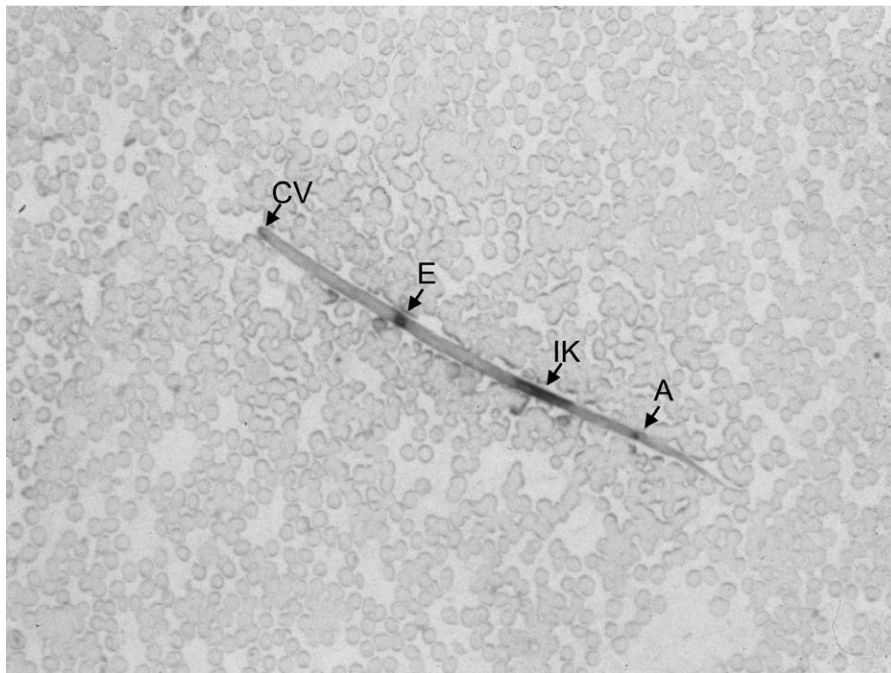


Fig. 1: *Acanthocheilonema dracunculoides* microfilaria showing acid phosphatase activity at the cephalic vesicle (CV), excretory pore (E), 'Innenkörper' (IK) and anal pore (A).

#### ACKNOWLEDGEMENTS

The senior author would like to acknowledge Mrs A. Lourens from the library of the Faculty of Veterinary Science for her relentless effort in obtaining articles from overseas.

#### REFERENCES

1. Balbo T, Abate O 1972 Histochemical differentiation of microfilariae of *Dirofilaria immitis*, *Dirofilaria repens* and *Dipetalonema* sp. *Parassitologia* 14: 239–244
2. Baylis H A 1929 *A manual of helminthology medical and veterinary*. Baillière, Tindall and Cox, London
3. Bell D 1967 Membrane filters and microfilariae: a new technique. *Annals of Tropical Medicine and Parasitology* 61: 220–223
4. Bernard J, Ben Osman F, Juminer B 1967 Enquête sur les helminthes parasites du chien (*Canis familiaris* L.) à Tunis-ville. *Archives de l'Institut Pasteur de Tunis* 44: 1–89
5. Bolio M E, Montes A M, Gutierrez C, Alonso F D, Bernal L J, Sauri C H, Rodríguez-Vivas R I 2002 Hallazgos clínicos en perros parasitados por *Dipetalonema dracunculoides*. *Archivos de medicina veterinaria* 34: 283–286
6. Chauve C M 1990 *Dirofilaria repens* (Railliet et Henry, 1911), *Dipetalonema reconditum* (Grassi, 1890), *Dipetalonema dracunculoides* (Cobbold, 1870) et *Dipetalonema grassii* (Noé, 1907): quatre filaires méconnues du chien. *Pratique Médicale et Chirurgicale de l'Animal de Compagnie* 25: 293–304
7. Cobbold T S 1870 Description of a new

- generic type of entozoon from the aardwolf (*Proteles*); with remarks on its affinities, especially in reference to the question of parthenogenesis. *Proceedings of the Zoological Society of London*: 9–14
8. Fraga de Azevedo J 1943 On the presence of *Dipetalonema dracunculoides* (Cobbold 1870) among dogs in Portugal. Contribution to the study of its morphology. *Anais do Instituto de Medicina Tropical* 1: 105–114
9. Gedoelst L 1916 Notes sur la faune parasitaire du Congo Belge. *Revue Zoologique Africaine* 5: 1–90
10. Jansen J, Peeters M E, Boersema J H, Cremers H J W M 1988 *Dipetalonema dracunculoides* (Cobbold 1870) (Nematoda: Dracunceridae) bij een geïmporteerde hond. *Tijdschrift voor Diergeneeskunde* 113: 537–538
11. Levine N D 1980. *Nematode parasites of domestic animals and of man* (2nd edn). Burgess Publishing, Minneapolis, Minnesota
12. Macchioni G 1982 Ancylostomiasis of wild carnivore and visceral larva migrans in man. *Acta Mediterranea di Patologia e Tropicale* 1 (1. Suppl.): 125–127
13. Marconcini A, Magi M, Macchioni G, Sasseti M 1996 Filariasis in foxes in Italy. *Veterinary Research Communications* 20: 316–319
14. Morel P C 1959 Les helminthes des animaux domestiques de l'Afrique occidentale. *Revue d'Élevage et de Médecine Vétérinaire des Pays Tropicaux* 12: 153–174
15. Nelson G S 1963 *Dipetalonema dracunculoides* (Cobbold, 1870), from the dog in Kenya: with a note on its development in the louse-fly, *Hippobosca longipennis*. *Journal of Helminthology* 37: 235–240
16. Nelson G S, Heisch R B, Furlong M 1962 Studies in filariasis in East Africa II. Filarial infections in man, animals and mosquitoes on the Kenya coast. *Transactions of the Royal Society of Tropical Medicine and Hygiene* 56: 202–217
17. Olmeda-García A S, Rodríguez-Rodríguez J A, Rojo-Vázquez F A 1993 Experimental transmission of *Dipetalonema dracunculoides* (Cobbold 1870) by *Rhipicephalus sanguineus* (Latreille 1806). *Veterinary Parasitology* 47: 339–342
18. Ortega-Mora L M, Gomez-Bautista M, Rojo-Vázquez F A 1989 The acid phosphatase activity and morphological characteristics of *Dipetalonema dracunculoides* (Cobbold, 1870) microfilariae. *Veterinary Parasitology* 33: 187–190
19. Ortega-Mora L M, Rojo-Vázquez F A 1988 Sobre la presencia de *Dipetalonema dracunculoides* (Cobbold, 1870) en el perro en España. *Revista Ibérica de Parasitología* 48: 187–188
20. Pandey V S, Dakkak A, Elmamoune M 1987 Parasites of stray dogs in the Rabat region, Morocco. *Annals of Tropical Medicine and Parasitology* 81: 53–55
21. Railliet A, Henry A 1911 Filaires à embryons sanguicoles de *Hyena crocuta* Erxleben [Discussion]. *Bulletin de la Société de Pathologie Exotique* 5: 630–631
22. Railliet A, Henry A, Langeron M 1912 Le genre *Acanthocheilonema* Cobbold, et les filaires péritonéales des carnivores. *Bulletin de la Société de Pathologie Exotique* 5: 392–395
23. Rao M A N 1938 *Dipetalonema dracunculoides* (Cobbold, 1870). *The Indian Journal of Veterinary Science and Animal Husbandry* 8: 127–130
24. Rioche M 1960 Présence de *Dipetalonema dracunculoides* (Cobbold, 1870) chez le chien dans la Région d'Algier. *Archives de l'Institut Pasteur d'Algérie* 38: 386–398
25. Rodríguez J F 1990 *Dirofilaria immitis* y otras parasitosis filariales. Incidencia, diagnóstico, tratamiento y prevención. *Pequeños Animales* 2: 91–111
26. Sachs R 1976 Filarien in Körperhöhlen, subkutanem Bindegewebe und anderen Organsystemen bei Wildherbivoren in Ostafrika. In Ippen R, Schröder H D (eds), *Erkrankungen der Zootiere. Verhandlungsbericht des XVIII Internationalen Symposiums über die Erkrankungen der Zootiere*, Innsbruck, Österreich, 16–20 June 1976: 195–203
27. Seurat L G 1918 Contribution à l'étude de la faune parasitaire de la Tunisie. Nématodes. *Archives de l'Institut Pasteur de Tunis* 10: 243–275
28. Sonin M D 1975 *Filariata of animals and man and diseases caused by them. Part III. Filariidae, Onchocercinae*. Amerind Publishing, New Delhi
29. Valcárcel F, Ferre I, Gómez-Bautista M, Rojo-Vázquez F A 1990 Diagnóstico de laboratorio de la infestación por *Dirofilaria immitis* en el perro. *Medicina Veterinaria* 7: 345–353